



RISKWISE

ISSUE 18 | OCTOBER 2019

SINGAPORE



The increase in orthodontics

WHAT ARE THE POTENTIAL LIMITATIONS AND THE RISKS THAT MIGHT ARISE?

TRIGEMINAL NERVE INJURIES

Causes of trigeminal alveolar nerve injury are varied

DENTISTRY AND PREGNANCY

The fear around treating pregnant patients

CASE STUDIES

Practical advice from real life scenarios

Contents



04 The increase in orthodontics and the risks that might arise

Dentolegal adviser Dr Simon Parsons looks into the complexity of orthodontics, the potential limitations and the risks that might arise.



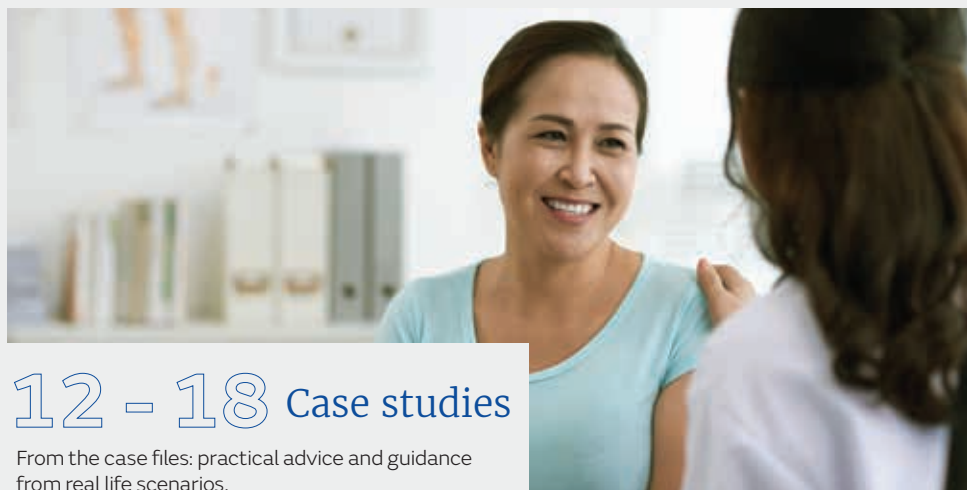06 Trigeminal nerve injuries related to restorative treatment

Professor Tara Renton, specialist in oral surgery, looks into 'prevention first'.



08 Dentistry and pregnancy

Leonie Callaway, professor of medicine at the University of Queensland, looks at the important issue of dentistry and pregnancy.



12 - 18 Case studies

From the case files: practical advice and guidance from real life scenarios.

Editor

Anna Francis

Production

Emma Senior

Design

Carl Watson

Contributors

Simrit Ryatt / Louise Eggleton / Jim Lafferty

Print

Sampoorna Printers

Editorial

DR JAMES FOSTER

Head of Dental Services Australasia/Asia



WELCOME TO THIS LATEST EDITION OF **RISKWISE, DENTAL PROTECTION'S FLAGSHIP PUBLICATION, OFFERING THE LATEST INFORMATION ON DENTAL TOPICS AND ADVICE FROM OUR DENTOLEGAL CONSULTANTS AND PROFESSIONAL EXPERTS.**

I have been fortunate enough to have travelled through Asia recently and had the pleasure of meeting many members. Providing presentations based upon our experience of handling cases in Asia for several decades is always an honour. I was grateful for the opportunity to use examples of such cases to try and help colleagues to minimise the risk of professional challenge, but at the same time – and through the same processes – build their professional reputation and the success of their practice.

ALSO IN THIS ISSUE

Professor Tara Renton, who has spoken at many Dental Protection events, has kindly provided an article on trigeminal nerve injuries related to restorative treatment. The article explores the cause of such injuries and how we can minimise the risk of them occurring.

Professor Leonie Callaway helpfully explores some of the issues around dentistry and pregnancy, where perhaps a lack of clear understanding can limit clinical care, often leading to problems, dissatisfaction and the development of complaints down the line.

Following these articles, we have a range of case studies reflecting real-life situations that members have experienced – all of which are followed by some helpful learning points and guidance specific to the circumstances.

The feedback we receive indicates that many dental members aren't fully aware of the professional development offered by Dental Protection, so I would urge you to visit our online learning centre, Prism, and see just what is available and how it could be of benefit to you.

As a member of Dental Protection, you have access to some of the best dental experts in the world. Dental Protection is dedicated to protecting members and their reputations, and with over 40 years of experience and expertise assisting healthcare professionals in Asia, we are best placed to help you should things go wrong.

WEBINARS AND WORKSHOPS

As highlighted in the previous edition of *Riskwise*, Dental Protection has been hosting a series of webinars that have proven to be very popular. These webinars give you an opportunity for real-time question and answer sessions during the live broadcast and enable you to have the expertise of Dental Protection brought directly to you.

The latest workshop, 'Building Resilience and Avoiding Burnout' recognises the issues that many practitioners face. We also appreciate that a case may weigh heavily upon an individual clinician and would like to remind members about the counselling service we offer. Whether you are suffering from stress and anxiety as a result of complaints, claims, or dental council hearings, this service is tailored to your requirements. It is delivered by fully trained, qualified and registered psychologists and counsellors and is entirely independent and confidential.

As always, I am keen to receive your feedback about our publications and, in particular, would like to know what subjects you might like to see featured in future issues of *Riskwise*.

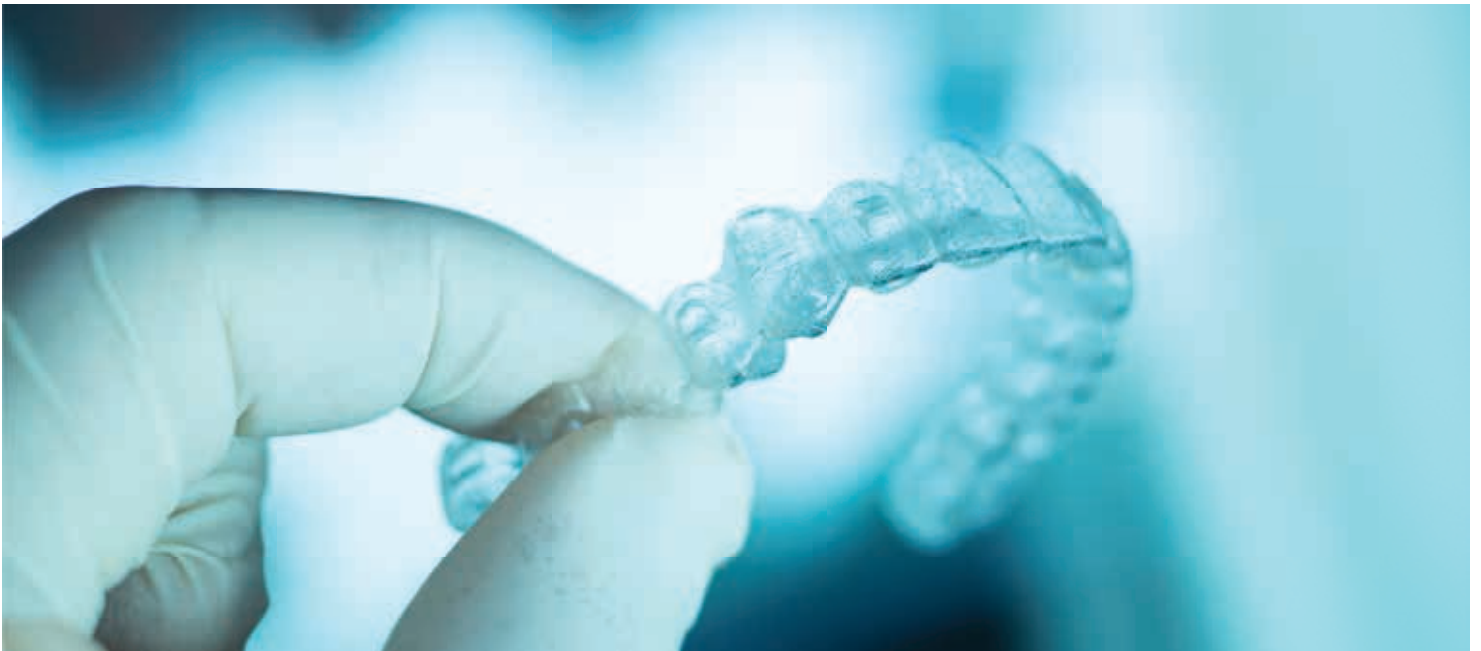Please feel free to contact me at the email address below.

Best wishes,

Dr James Foster LLM BDS MFGDP (UK)

Head of Dental Services Australasia/Asia

james.foster@dentalprotection.org



The increase in orthodontics and the risks that might arise

With the clear aligner market increasing around the world, dentolegal adviser Dr Simon Parsons looks into the complexity of orthodontics, the potential limitations and the risks that might arise.

The worldwide USD \$3bn per annum clear aligner market is forecast to continue growing by around 21% over the five year period of 2018-2023.¹

General dentists with limited prior orthodontic training may be drawn to the promise of aligner systems that seem almost to 'do it all' and are increasingly offering this treatment to their patients. This opportunity to augment practice revenue, and grow one's clinical skill set, brings in its wake the increased likelihood of complaints and claims when the treatment outcome is compromised or patient expectations have not been met.

The provision of orthodontic treatment by general dental practitioners can be risky, even when it involves modest tooth movement. The importance of case selection cannot be overstated and unmet expectations can trigger litigation. When cases arise, it is not uncommon for general practitioners to be questioned about the extent and adequacy of their training to undertake orthodontic treatment.

A recent study carried out in the United States investigated the different perceptions of case complexity between orthodontists, GPs, orthodontic trainees and dental students.

The study concluded that orthodontists and orthodontic trainees "...had better judgments for evaluating orthodontic case complexity. The high correlation between orthodontic professionals' perceptions and DI scores suggested that additional orthodontic education and training have an influence on the ability to recognize case complexity".²

LOOKING AT THE LIMITATIONS

Although clear aligner systems have some clinical advantages and are based on sophisticated technology, they have limitations in the amount and type of tooth movement that can be achieved.³

Furthermore, there is some evidence of unexpected risks with aligner therapy, such as breathing difficulty, swelling of the lips, throat and tongue and even anaphylaxis.⁴ These risks must be appropriately managed.

As a third party usually provides the initial treatment planning for aligner cases, it may be tempting to delegate the decisions to an unseen party who is relying on supplied photographs, scans and models. Inexperienced dentists may not recognise that targets for tooth movement, derotation

and intrusion or extrusion are ambitious. The achievement of a successful aesthetic and functional result may well depend on completing all these actions, and the treating dentist will be responsible for the treatment outcome should it fail to meet patient expectations.

The high costs of orthodontic care, and the patients' capacity to evaluate the outcome, will go a long way towards the patient's perception of success. There will undoubtedly be high expectations on the part of the patient and, if these are not met, referral for specialist treatment may be indicated which will incur additional costs. Uncertainty can exist in the minds of general dentists and patients as to who is responsible for any costs associated with corrective treatment, or when a patient transfers to another practitioner prior to completion. So how might dentolegal risk be reduced when general dentists consider offering clear aligner treatment?

PRE-TREATMENT

Making an accurate diagnosis is the first step in understanding patient suitability for treatment by a general dentist. Poor case selection is frequently the root cause of dissatisfaction down the line. Pre-treatment

assessment might include detection of unfavourable facial profiles, marked asymmetries, a deep overjet and overbite or substantial midline discrepancies which may prove difficult to manage with clear aligners alone. It can be tempting to offer patients an improvement in tooth position through aligner therapy while unknowingly ignoring underlying factors that may make success almost impossible to achieve without specialist care.

Appealing as it may be to take on a case, it is always wise to discuss alternatives to clear aligner therapy with a patient, including such options as no treatment and specialist referral. Simply because a patient has attended for a consultation or sought information about clear aligners – sometimes as a result of internal marketing – does not mean that this is the only option that should be considered. The dentist must consider all other viable alternatives in consultation with the patient as part of the consent process.

Understanding the patient's expectations from the outset is essential to avoid future disappointment. Some patients who seek aligner therapy may present with minor orthodontic needs, but may expect absolute perfection in tooth alignment. Indeed, their expectations may involve other factors which they, themselves, do not fully understand such as the shape of individual teeth or the colour of some or all of their teeth. Any non-compliance with aligner wear or post-treatment retention may compromise the outcome and achievement of ideal results. The clinical presentation, diagnosis, treatment options, risks, benefits and costs, importance of compliance with advice and tempering of unrealistic patient expectations should all be documented in the clinical records together. These entries will be scrutinised in the event of any investigation or inquiry.

DURING TREATMENT

Problems such as speech concerns, excessive salivation, mouth soreness, aligner breakage and aligner loss may all impact on treatment effectiveness. Patients may dislike attachments placed on teeth, fail to use elastics or other adjuncts to treatment or decline to undergo interproximal tooth reduction. A prospective patient needs to be aware of these issues, before and during treatment, so that there are no surprises and disagreement as treatment progresses.

Despite the best efforts of both the patient and the clinician, sometimes treatment does not progress as well as expected. Dentolegal risk can be reduced through regular patient reviews in surgery rather than an 'arm's length' approach of minimal treatment supervision. Early detection of problems enables prompt correction where

possible and helps to avoid escalation of problems and further patient dissatisfaction. Our experience is that it is wise to refer patients to specialist providers promptly whenever the efficacy of aligner treatment seems to be in doubt. This can mitigate the risk of further complications while also optimising the chance of a favourable overall treatment outcome.

POST TREATMENT

While all orthodontic treatment carries risk, some risks may persist upon treatment completion. Patients may be unhappy with the overall treatment outcome and request refinement, retreatment or referral. The general dentist will need to evaluate with the patient how closely the result matches with the pre-treatment projection and the individual patient's long term expectations. Retreatment or referral may carry financial implications for both parties and is best understood before treatment commences (through an explanation) rather than after treatment has finished (via an excuse). Devitalised teeth, relapse, or – particularly with aligners – a failure to achieve adequate occlusal contacts may also occur. Effective retention is essential if relapse is to be avoided.

CASE ASSESSMENT

To manage risk with clear aligner cases, careful case assessment is key. Some aligner systems allow prediction of the final outcome and alteration of the treatment parameters to suit the objectives of the patient and the clinician. These are preferred over a 'one size fits all' approach. Dental Protection recommends any treatment proposal be thoroughly checked prior to finalisation of the treatment plan by the treating clinician to ensure that proposed tooth movements are within a predictably reliable range.

General practitioners have the advantage of coordinating a patient's total dental care, and this provides scope for considering preventive and restorative needs within the overall plan. The general practitioner is well placed to consider any pre-existing limitations to effective tooth movement, such as implants and bridgework, while also understanding how to manage restoration fracture or loss during aligner treatment. Are you able to deal with complications if they arise? Do you have the knowledge and skill necessary to identify and manage likely complications that might occur during the treatment phase?

As with any treatment that incurs significant financial and time costs, it is always prudent to approach clear aligner therapy alongside other necessary treatment rather than as a standalone treatment. Despite a patient's understandable desire to get on with the

cosmetic component first, it is often wise to schedule orthodontic treatment towards the latter stages of any treatment plan. Ensuring all periodontal, endodontic and restorative issues have been addressed first means that the patient is more likely to be a suitable candidate for orthodontic treatment.

LEARNING POINTS

- Take models/scans, radiographs and photographs as part of a preoperative assessment and evaluate these thoroughly before discussing the feasibility of aligner therapy with your patient.
- Clearly outline the costs of care, including the costs of replacement aligners and retainers. Ensure patients understand when payments are due.
- Carefully explain the process, including composite resin attachments if required, and the importance of compliance. Explain that, occasionally, a specialist referral may be necessary if things do not go to plan. Establish who will be responsible for the costs of such a referral.
- Be on your guard towards patients with unrealistically high expectations or those who seem in a hurry to commence treatment without due consideration to their other treatment needs (such as caries or periodontal issues).
- If in any doubt as to the likelihood of success, consider referral of a patient to a more experienced colleague or specialist.
- If you are not a specialist orthodontist, make sure that the patient is aware of this and offer a referral to a specialist as one of the options for treatment.

REFERENCES

1. Reuters.com. (2019). Clear Aligners Market 2018 Global Trends, Key Vendors Analysis, Industry Growth, Import - Reuters.
2. Heath EM, English JD, Johnson CD, Swearingen EB, Akyalcin S. Perceptions of orthodontic case complexity among orthodontists, general practitioners, orthodontic residents, and dental students. *Am J Orthod Dentofacial Orthop*. 2017 Feb;151(2):335-341. doi: 10.1016/j.ajodo.2016.06.045.
3. Ke Y, Zhu Y, Zhu M. A comparison of treatment effectiveness between clear aligner and fixed appliance therapies. *BMC oral health* 19(1), 24. doi:10.1186/s12903-018-0695-z (2019)
4. Allareddy, Veerasathpurush et al. (2017). Adverse clinical events reported during Invisalign treatment: Analysis of the MAUDE database. *American Journal of Orthodontics and Dentofacial Orthopedics*, Volume 152, Issue 5, 706 - 710

Trigeminal nerve injuries related to restorative treatment

Causes of trigeminal alveolar nerve injury (TNI) are varied, but many occur that are related to restorative dentistry. Professor Tara Renton, specialist in oral surgery, looks into 'prevention first' and recommended management of nerve injuries.

PREVENTION

Neuropathy caused by local block injections is a well-recognised complication throughout medicine, anaesthesia and dentistry. However, dentistry is the only specialty that still trains clinicians to aim for nerves rather than avoid neural contact (often using ultrasound), which likely explains the continued prevalence of local anaesthetic (LA)-related nerve injuries in dentistry.

There is evidence, using ultrasound, that the benefits of a proximal injection of LA to the inferior alveolar nerve (IAN) are not related to efficacy of the inferior dental block (IDB). A close injection to the nerve is therefore not required. However, what is frequently overlooked is the need to wait for eight to ten minutes for optimal pulpal anaesthesia, and additional repeated IDBs will not improve the success of anaesthesia.

A recent report highlights that the prevalence of IDB-related nerve injuries in UK general dental practice is 1:14,000 blocks for temporary nerve injury, or 1:56k IDBs with patients experiencing permanent lingual or inferior alveolar nerve injury, of which 25% of nerve injuries are permanent.¹

Nerve injury due to LA is complex. The nerve injury may be physical (needle, compression due to epineural or perineural haemorrhage) or chemical (haemorrhage of LA contents). Thus the resulting nerve injury may be a combination of peri-, epi- and intra-neural

trauma causing subsequent haemorrhage, inflammation and scarring, resulting in demyelination (loss of nerve lining).

Only 1.3-8.6% of patients get an 'electric shock' type sensation on application of an IAN block and 57% of patients suffer from prolonged neuropathy having not experienced the discomfort on injection, so this is not a specific sign.²

Routine practice in Europe and USA involves warning patients of potential nerve injury in relation to dental injections.

INFILTRATION DENTISTRY AVOIDING BLOCK ANAESTHESIA

A 2014 survey of German dental LA practice found that 74% of dentists were using infiltration dentistry routinely, avoiding the use of inferior dental blocks (IDBs). Improved comfort was reported by patients who had a preference for having full lingual sensation and shorter duration LA anaesthesia after dental treatment.³

Further evidence to support infiltration dentistry successfully includes a study by Evans, Nusstein and Drum et al⁴, which found 4% articaine to be more effective than 2% lidocaine for lateral incisors but not molars, and a recent randomised and controlled trial, which found a statistically significant difference supporting use of 4% articaine in place of 2% lidocaine for buccal infiltration in patients experiencing irreversible pulpitis in maxillary posterior teeth.⁴ Other studies however – such as that conducted by Oliveira et al – reported no clinical superiority for this injection.

There is evidence supporting the significantly increased rates of pulpal anaesthesia using infiltration anaesthesia, when compared with

IDB anaesthesia, particularly for premolar and incisor teeth.¹ Similarly, a recent systematic review reports that articaine is 3.4 times more effective for pulpitic mandibular molars when compared with lidocaine, but there is no difference between articaine and lidocaine maxillary infiltrations or IDBs.⁵

Several reports of supra periosteal infiltration anaesthesia suggest that it is not only sufficient for posterior mandible implant surgery but may be protective of the IAN.⁶ When it comes to periodontal and implant surgery, the standard care is infiltration LA, while intraligamental anaesthesia for extractions and avoiding IDBs is also gaining popularity.⁷ Paedodontic extractions do not require IDBs as the bone is very porous and susceptible to absorption of infiltrative anaesthesia.

PREVENTION OF LA NERVE INJURIES IS POSSIBLE

These simple steps may minimise LA-related nerve injuries:

- Avoid high concentration LA for IDBs (use 2% lidocaine as standard). There is increasing evidence that higher concentration agents are more neurotoxic and therefore more likely to cause persistent IDB related neuropathy.
- Avoid multiple blocks where possible.
- Avoid IAN blocks by using high concentration agents (articaine) with infiltration-only anaesthesia. Infiltration dentistry avoids the use of IDBs, therefore preventing LA-related nerve injury, for which there is no cure.



There are two main issues currently for LA: changing practice in using tailored LA techniques rather than always reaching for the IDB, and consenting patients regarding potential nerve injury.

CONSENT FOR LA

Patients are routinely warned of the risk of nerve injury when undergoing epidural or spinal injections. Reports estimated that nerve injury from neuroaxial blocks (epidurals, spinals and combined epidural with spinals) resulted in sensory or motor nerve injury in 1 in 24-54,000 patients (and paraplegia or death in 1 in 50-140,000 patients).⁸

Germany already has a legal precedent to warn all patients of the risk – something that was originally suggested in the US.⁹ With Montgomery setting consent principles based upon what is material to the patient, warning patients of the risk of TNIs, and their unpleasant consequences, should now be routine.¹⁰

TAILORED LA TECHNIQUE

Infiltration dentistry avoids the use of IDBs in most cases. IDBs may only be needed for lower posterior molar complex endo, restorative and extraction procedures, thus preventing LA-related nerve injury.

By avoiding IDBs there is less risk of injury to the lingual and inferior alveolar nerves which, though rare, is debilitating to the patients and has no cure. This technique requires less skill, causes less discomfort for the patient during the injection and avoids unnecessary lingual anaesthesia after dental treatment.

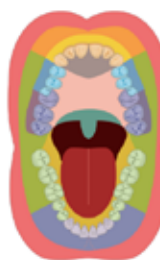FIGURE 1. (Thanks to Andrew Mason at Dundee University for anatomical picture)

Minimise nerve injuries by using infiltration dentistry and avoid IDBs

Maxillary dentistry can be performed using Lidocaine 2% with adrenaline buccal infiltration for most procedures. There is no additional benefit using 4% Articaine infiltration. For **extractions** use additional intraseptal LA. No palatal or incisal blocks are required.

Only procedures needing IDB

- Second third molar restorations if infiltration does not work
- Endodontic procedures may only require IDBs for mandibular second and third molars
- Complex extraction of molars



Mandibular 7s and 8s for **perio, restorations or implants**. Articaine 4% buccal infiltration with additional Lidocaine 2% intraseptal or intracrestal OR lingual infiltrations. For **extractions**, Articaine 4% buccal infiltration plus lidocaine intraligamental may be required.

Mandibular 1st molars for **perio, restorations or implants**. Articaine 4% buccal infiltration Plus Lidocaine intra crestal, intraseptal or Lingual infiltration. For **extractions** buccal Articaine 4% infiltration and Lidocaine 2% intra-ligamental.

Mandibular incisors, canines premolars for **perio, restorations or implants**. Articaine 4% or Lidocaine 2% buccal mental infiltration (NOT block) for **extractions**, add intraseptal, lingual intra-ligamental if required.

REFERENCES

1. Renton T, Adey-Viscuso D, Meechan J et al. Trigeminal nerve injuries in relation to the local anaesthesia in mandibular injections. *British Dental Journal* 2010;209:E15-E15. doi:10.1038/sj.bdj.2010.978
2. Smith MH, Lung KE. Nerve injuries after dental injection: a review of the literature. *Journal of the Canadian Dental Association* 72 (6) 559-564
3. Pogrel M, Schmidt B, Sambajon V et al. Lingual nerve damage due to inferior alveolar nerve blocks. *The Journal of the American Dental Association* 2003;134:195-199. doi:10.14219/jada.archive.2003.0133
4. Evans G, Nusstein J, Drum M et al. A Prospective, Randomized, Double-blind Comparison of Articaine and Lidocaine for Maxillary Infiltrations. *Journal of Endodontics* 2008;34:389-393. doi:10.1016/j.joen.2008.01.004
5. Kung J, McDonagh M, Sedgley C, Does Articaine Provide an Advantage over Lidocaine in Patients with Symptomatic Irreversible Pulpitis? A Systematic Review and Meta-analysis. *Journal of Endodontics* November 2015 Volume 41, Issue 11, Pages 1784-1794. https://doi.org/10.1016/j.joen.2015.07.001
6. Etoz OA, Nilay E, Demirbas AE. Is supraperiosteal infiltration anesthesia safe enough to prevent inferior alveolar nerve during posterior mandibular implant surgery? *Medicina Oral Patologia Oral y Cirugia Bucal* 2011 May 1;16 (3)e386-9. doi: 10.4317/medoral.16.e386
7. Dumbidge HB, Lim MV, Rudman RA, Serraon A. A comparative study of anesthetic techniques for mandibular dental extractions. *American Journal of Dentistry* 1997;10:275.
8. The National Royal College of Anaesthetists. *Audit Recipe Book 3rd edition*. 2012. Accessed 31/07/2019 at: https://www.rcoa.ac.uk/document-store/audit-recipe-book-3rd-edition-2012
9. Orr DL, Curtis WJ. Obtaining written informed consent for the administration of local anesthetic in dentistry. *Journal of the American Dental Association* 1939 136(11):1568-71. doi: 10.14219/jada.archive.2005.0090
10. Montgomery v Lanarkshire Health Board [2015] SC 11 [2015] 1 AC 1430.

Dentistry and pregnancy

Leonie Callaway, professor of medicine at the University of Queensland, looks at why it's so important for dentists to understand some of the issues around dentistry and pregnancy



One of the main difficulties dentists struggle with is their fear around treating pregnant patients. It is an emotive time and everyone is aware of the need to ensure the very best outcomes for the foetus. As a result of this fear, and a lack of clear understanding, clinical care can often be more limited than it should be, with a series of unfortunate and unintended consequences for both mother and child. The purpose of writing this is to try to put your mind at ease, and provide some clear guidelines about what is and is not okay during pregnancy.

My area of expertise is as an obstetric physician. We care for women with medical disorders in pregnancy and therefore have particular expertise in the issues around radiation, drugs and surgery in pregnancy, the provision of pre-conception care, and the care of women with high risk pregnancies as a result of pre-existing illness or illness that arises during the pregnancy.

Globally, there are obstetric physicians in all of the major tertiary obstetric hospitals. We work in multidisciplinary teams with obstetricians, neonatologists, pharmacists, radiologists and specialists of all kinds with an interest in pregnancy (eg rheumatology, endocrinology, cardiology, nephrology and oncology).

If you ever have a tricky question regarding care for a pregnant woman, feel free to call your closest tertiary maternity hospital and ask to speak to the obstetric medicine registrar or physician who is on call for the maternity service. They should be able to provide you with advice, and if they do not know the answer to your question, they will be happy to point you in the direction of help. Pharmacists can also be invaluable in providing advice regarding drugs in pregnancy.

THE LEVEL OF CARE REQUIRED

We know that pregnancy worries many healthcare providers and results in fear-based clinical decisions that are often not in the best interest of the mother or foetus. As a general observation, pregnant women often do not receive the care they need from a range of health professionals, due to misconceptions about medications, radiology and surgery during pregnancy.

We have seen pregnant women hobbling around with undiagnosed fractures because their doctor was fearful of doing an x-ray during pregnancy, or struggle with a sudden deterioration in their asthma because their doctor thought their asthma medication was unsafe during pregnancy. We also see women with toothache and dental sepsis because dentists were afraid to treat them.

Most dentists find it reassuring to know that the care they might consider providing is quite minor in terms of risk, compared to what goes on for pregnant women on a day-to-day basis in hospitals. For example, a dental radiograph results in a foetal radiation dose of 0.0001 rads, compared to a chest radiograph involving 0.001 rads.

We teach all medical students that if a pregnant woman requires a chest radiograph at any point during her pregnancy, the radiation dose to the foetus is so insignificant, that the risk of not doing the radiograph and not assessing the lungs and heart properly may far outweigh any minor risk of extremely low doses of foetal radiation.

Pregnant women who develop cancer are often given multiple cycles of chemotherapy during pregnancy and women who develop appendicitis, cholecystitis or hypercalcaemia from parathyroid adenomas are all cared for with appropriately-timed surgery during pregnancy. So, in comparison to the kinds of medications, surgical procedures and radiation exposure that is required to care for pregnant women on a daily basis, dental procedures and dental radiation generally falls into the relatively minor category.





WHAT YOU NEED TO KNOW

There are a few key messages for dentists providing care for pregnant women or women within the reproductive age range:

1. Women of reproductive age need excellent oral health prior to falling pregnant.

Ideally, women considering a pregnancy should ensure that all major necessary dental work is undertaken prior to pregnancy if possible.

Dentists should enquire about pregnancy plans when women of reproductive age have dental issues identified, and encourage them to complete treatment plans prior to conception. This provides peace of mind for all involved. Adverse events such as miscarriage, congenital anomalies, growth restriction and premature delivery are common. People tend to associate adverse events with whatever happened to them recently. Providing excellent preconception dental care prevents women associating their dental care with common adverse pregnancy events in their own mind. It also reduces pregnancy associated anxiety for the dentist, which is a well-documented problem.

2. Required routine and emergency dental treatment can be carried out at any time during pregnancy.

There are multiple guidelines to encourage and reassure dentists about providing regular and emergency dental care for pregnant women. References to these guidelines are on the following page.

3. Dental imaging should be used when required.

Fear of dental radiation during pregnancy is generally misplaced. The foetal exposure from dental radiation is vanishingly low. Therefore, if there is concern about dental infection during pregnancy and dental radiation is required to assist in determining an appropriate treatment plan, women should be strongly reassured about the risk benefit ratio of dental radiation.

Untreated dental sepsis can trigger pre-term birth, and result in overwhelming maternal infection. High quality dental care, including appropriate dental imaging, can prevent these adverse outcomes.

4. Pregnant women from 28 weeks onward need careful positioning in a dental chair.

In advanced pregnancy, women are often very uncomfortable lying on their back and can develop hypotension from the foetus compressing the inferior vena cava. Therefore, from about 28 weeks onwards, a wedge or rolled up towel should be placed

under one side of the woman's back while in the dental chair, to ensure the foetus is not sitting on top of the vena cava.

5. Non-steroidal anti-inflammatory drugs need care during pregnancy.

In the third trimester (from 28 weeks of gestation onwards), non-steroidal anti-inflammatory drugs (NSAIDs) should be avoided, due to significant foetal risks. These drugs are associated with persistent pulmonary hypertension of the newborn due to premature constriction of the patent ductus arteriosus, foetal renal injury, oligohydramnios (reduced amniotic fluid), necrotising enterocolitis and neonatal intracranial haemorrhage. Unfortunately, the constriction of the ductus arteriosus in the foetus can be related to even a single dose of NSAIDs.

For dental pain relief, we recommend paracetamol. If additional pain relief is required opioid based analgesia is safer, and we would suggest the use of codeine or oxycodone. NSAIDs can be considered in the second trimester (12-28 weeks) if absolutely necessary. If women have been taking over-the-counter NSAIDs for dental pain in the third trimester, encourage them to see their obstetrician so an ultrasound scan to assess foetal wellbeing can be arranged.



6. Individualised decision-making is often required, and communication with other healthcare professionals involved in the woman's care is strongly recommended.

Each woman's situation is unique. There are many variables in clinical decision-making for pregnant women who require medications, imaging and surgical procedures. These variables include the woman's own preferences, the stage of pregnancy, delivery plans, foetal growth and wellbeing, weighing of risks and benefits, access to specialised services, newly published research, variations in guideline-based recommendations regarding the safety and acceptability of various medications (eg local anaesthetics, nitrous oxide, antibiotics), decision-making in the context of limited information, and the skills of the healthcare providers involved.

CONCLUSION

All of the guidelines encourage communication between the dentist and the woman's other healthcare providers. We strongly recommend good communication with the woman's obstetrician, general practitioner or pregnancy healthcare team in cases where the best plan of action is unclear. We also recommend seeking expert, up-to-date guidance in situations where the published evidence and guidelines lack sufficient clarity to guide decision-making in a particular woman's unique situation.

HELPFUL READING

American Dental Association Guidelines on Dental Care during Pregnancy: <https://www.ada.org/en/member-center/oral-health-topics/pregnancy>

Oral health care during pregnancy and through the lifespan. Committee Opinion No. 569. American College of Obstetricians and Gynecologists. *Obstet Gynecol* 2013 (Reaffirmed 2017);122:417 -22.

CDC National Consensus Statement regarding Oral Health Care During Pregnancy <https://www.mchoralhealth.org/PDFs/OralHealthPregnancyConsensus.pdf>.

Guidelines for diagnostic imaging during pregnancy and lactation. Committee Opinion No. 723. American College of Obstetricians and Gynecologists. *Obstet Gynecol* 2017;130:e210 -6.

Lowe S. Diagnostic radiation in pregnancy: risks and reality. *Aust N Z Journal Obstet Gynaecol*. 2004. June; 44(3):191-6.

Lopes LM, Carrilho MC, Francisco RP, Lopes MA, Krebs VL, Zugaib M. Fetal ductus arteriosus constriction and closure: analysis of the causes and perinatal outcome related to 45 consecutive cases. *J Matern Fetal Neonatal Med*. 2016; 29(4):638-45.

Ouanounou A, Hass DA. Drug therapy during pregnancy: implications for dental practice. *Br Dent J*. 2016 Apr;22(8):413-417.

Kelaranta A, Ekholm M, Toroi P, Kortensniemi M. Radiation exposure to foetus and breasts from dental X-ray examinations: effect of lead shields. *Dentomaxillofac Radiol*. 2016 Jan; 45(1):20150095.

Case study

A misaligned claim



Mrs T attended an appointment with her regular dentist. The dentist was already aware through previous discussions that she was considering a course of orthodontic treatment to address the mild crowding in her upper and lower arch, along with aligning the upper central incisors that were mesially inclined.

Mrs T informed the dentist that she now was ready to move forwards with orthodontic treatment. The dentist had considerable experience in providing short-term orthodontic aligner treatment and carried out a full orthodontic assessment and provided the patient with treatment options, along with option of referral for potential fixed braces with a specialist colleague. Mrs T declined the referral and so the discussion with the dentist was limited to aligner treatment. The patient was also given information about the anticipated costs of aligner treatment and made aware of the need for permanent retention after treatment had finished. Mrs T was asked to book the next appointment for a further discussion or to begin treatment should she wish.

At the following appointment, Mrs T said she was sure she wanted to begin treatment, so the dentist carried out the aligner treatment over the course of ten months. The patient was very happy with the final result and the dentist reiterated his recommendation that due to the original position of the mesially inclined upper central incisors, he considered it necessary to have both permanent fixed retention of the upper teeth and upper and lower removable retainers to guard against potential tooth movement in the future.

Mrs T declined fixed retention because she would not be able to floss. The dentist went on to remind her why permanent retention was necessary and the risk of relapse should she not observe a strict regime of wearing the retainers each and every night. She still refused and so the dentist provided upper and lower removable retainers, being sure to document all their discussions in the treatment records.

Mrs T continued to see the dentist for her routine dental care up until the dentist retired five years later. The practice was sold and all patients were informed of the dentist's retirement and that a new clinician would continue their care at the clinic.

Unexpectedly, three years later the dentist received a letter from a lawyer informing him that Mrs T was pursuing him for damages regarding treatment he had provided eight years previously. The dentist was shocked and disappointed to learn the identity of the patient, who he always felt he had enjoyed a good professional relationship with.

The dentist immediately contacted Dental Protection, who assisted him in obtaining more information.

It became apparent that Mrs T had been wearing her retainers routinely since the dentist provided his initial orthodontic treatment course all those years ago. However, Mrs T had complained that she had experienced a relapse of the orthodontic treatment and the retainers were no longer maintaining the alignment of her teeth.

Dental Protection requested that Mrs T was examined by a specialist orthodontist to establish the current clinical situation. The orthodontic report stated that Mrs T had experienced a mild relapse in alignment of the incisors, which had started to become mesially inclined once again. Mrs T was requesting that the original dentist pay for remedial treatment to correct the relapse in alignment of the upper anterior incisors, as she said she was informed the alignment of her teeth would be maintained if she wore the retainer every night.

The specialist orthodontist also examined the patient's retainer which was discovered to have two fracture lines present and a missing section in the upper anterior buccal aspect, that was allowing flex and movement of the retainer.

Based upon these findings, and the detailed treatment records clearly evidencing the patient and dentist discussion regarding the advice that permanent fixed retention was strongly recommended, Dental Protection was able to robustly defend the claim on behalf of the retired dentist and demonstrate the onus was on the patient to continue to wear a retainer fit for purpose and her refusal to accept the dentist's recommendations of fixed retention all those years ago.

LEARNING POINTS

- Always ensure you write detailed records of all key treatment discussions with your patient. In this situation, the information provided to the patient regarding the recommendation for permanent fixed retention – along with the warnings of potential relapse – was recorded. The patient continuing to wear a now defective retainer clearly demonstrated the dentist was not liable for the mild relapse.
- Even after retirement from clinical dentistry, a dentist can find themselves faced with a legal challenge for treatment provided a number of years ago.
- Occurrence-based protection with Dental Protection depends on the date on which an adverse incident occurs, and not the date that the matter is reported to us. This is important because it can often be years before a case is brought and fully resolved. This type of protection offers peace of mind, and in this instance, meant that Dental Protection was still able to provide assistance, at no further expense to the dentist.



Case study

Avoiding patient-led dentistry

Ms B was suffering from pain that kept her awake at night. An examination by the dentist established tooth 27 was the cause of discomfort. The 27 had extensive dental decay and a missing buccal wall. Ms B had an otherwise intact arch and was keen to save the tooth – she did not want a dental extraction.

The dentist explained that endodontic treatment carried no guarantee of success, especially with the extent of damage to the enamel walls, and extraction was offered as the only realistic alternative.

Ms B was quite persistent in her demands for root treatment, along with a full coverage crown, and was unwilling to be referred to a specialist. The dentist felt pressurised by the patient and embarked upon the endodontic treatment against her better judgement.

Five visits later, only two of the canals had been located and the third may have been perforated as it bled on instrumentation. This was discussed with Ms B and the tooth was dressed.

Whilst the endodontic treatment was becoming more complicated, Ms B was still unwilling to consider an extraction and was forceful in her request for the root treatment to be completed by the practitioner.

Further explanations were provided, but despite this Ms B remained convinced that a crown would solve the problem. She decided to visit a second dentist and was informed that the tooth had an incomplete root canal treatment.

The first dentist received a letter of complaint questioning why the endodontic treatment had not been completed in five visits, and why Ms B had been charged for this incomplete and unsuccessful treatment.

Whilst the clinical records were detailed, the practitioner was vulnerable in some areas regarding the clinical care provided. In terms of the preoperative assessment, the restorability status of the tooth at the outset was questionable. During the procedure the dentist could not place a rubber dam because of insufficient residual coronal tissue and, owing to a lack of anatomical landmarks, a perforation occurred. With hindsight, the practitioner realised that the decision to carry out root canal therapy intervention had been a poor one, and she should not have attempted the procedure in the first place.

The complaint was resolved by refunding Ms B for the initial endodontic treatment and contributing towards the cost of the second dentist's assessment.


Had Ms B pursued the matter with a claim for clinical negligence, the solicitors could potentially allege that Ms B had been subjected to an inappropriate procedure with associated pain and suffering.

LEARNING POINTS

- Be alert to patient-led dentistry and the demands of strong-willed patients. Unrealistic expectations should be identified and managed from the outset. The reasons why the treatment is inappropriate should be communicated effectively.
- Avoid being coaxed by persistent patients into carrying out treatments that have a slim to zero chance of success.
- Just because a patient consents to treatment, it doesn't necessarily mean that the treatment is appropriate.
- In this particular case, the complaint was resolved by a detailed letter of explanation and refund of fees.
- In trying to appease the patient, the dentist had spent more than three hours attempting treatment that was essentially doomed to fail, and then had to spend even more time managing the resulting complaint.
- This case highlights the dangers of attempting heroic dentistry; dentists are unlikely to be thanked for lack of success.
- Unrealistic expectations should be managed carefully from the outset.

Case study

Delayed postoperative healing following an extraction



Mrs C attended her dentist for an extraction of an unrestorable, fractured 37. The procedure was uneventful and postoperative instructions were provided in the usual way.

She returned a few days later in discomfort and the dentist diagnosed alveolar osteitis. The socket was irrigated and the dentist placed a medicated dressing in the socket. The dentist explained the diagnosis, advised Mrs C to take painkillers and offered to book a review three days later.

Mrs C seemed surprised about this and declined the appointment, as she had already taken two days off work to attend the clinic for the extraction and the emergency appointment. As there were no signs of infection, antibiotics were not prescribed, and she left fairly disgruntled.

Her husband returned to the clinic the next day shouting and behaving raucously. He complained to the receptionist that his wife was still in considerable pain following the extraction of her tooth, and stated that this was down to the poor standard of treatment provided by the dentist. He threatened to report the dentist to the press and the Dental Council, and said that he had already posted negative comments about the dentist on various social media sites.

The dentist in question was working in another clinic that day and was informed of this event by the Practice Manager. He then contacted Dental Protection for urgent advice as he was concerned about the impact of the critical social media commentary. He discussed the case with a dentolegal consultant and explained that although he was unaware of any press coverage to date, there were a handful of comments on social media attempting to undermine his credibility and professional reputation.

The press team at Dental Protection was asked to assist the member and advised the dentist that if he was contacted by the media for a comment, he should find out:

- the journalist's name
- the name of the publication
- the aspects of the care and treatment they were seeking comments on
- the deadline for a response
- the journalist's contact details, including phone number and email address.

The press team also provided the following helpful advice:

- Do not respond to any questions immediately – instead take some time to consider a response or to seek advice.
- Maintain your professionalism at all times and do not be tempted to discuss a patient's treatment in a public domain. If you cannot discuss the patient's treatment for confidentiality reasons then you should say so.
- Avoid saying 'no comment' as it sounds defensive. Ensure you come across as co-operative and inform the reporter that you will come back to them.
- Contact the Dental Protection press office for advice and liaise with your employer/practice where appropriate.

The dentist was reassured that the press team could liaise with journalists if necessary and provide a statement on his behalf.

Steps were also taken to address the negative comments made on social media: the administrator of the social media page was contacted and the unfair and inappropriate comments were asked to be removed.

The situation was amicably resolved by arranging for another dentist to review Mrs C. This dentist confirmed the diagnosis and explained to the patient that dry socket was a recognised complication, and that the pain would subside within a few days and the socket would heal.

It is always advisable to request Dental Protection's assistance from the outset when faced with unexpected clinical outcomes and/or complications that may lead to a patient complaint. In this situation, the dentist was able to identify a strategy to manage the adverse social media coverage and potential harm to his reputation by contacting Dental Protection immediately.

LEARNING POINTS

- **The dentist failed to warn the patient about the possibility of alveolar osteitis at the outset. Consequently, when the patient developed a recognised postoperative complication she became alarmed and blamed the dentist.**
- **An opportunity was also missed when the dentist realised that the patient left the clinic unhappy. It may have been worthwhile considering contacting the patient later on that evening to enquire how she was and provide further support and advice.**



Case study

I told the patient... but I didn't write it down

Mr L visited his dentist complaining of pain in the posterior maxilla area under his existing partial denture. Clinical examination revealed redness and tenderness over his upper left second molar.

A radiograph taken at the time of the examination revealed a buried root, that was clearly being irritated by the denture. As a temporary measure, the denture was adjusted and Mr L was advised that the retained root should be removed.

The radiograph also revealed the floor of the maxillary sinus was in very close proximity to the root. Whilst the extraction appeared to have been completed without too much difficulty, unfortunately unbeknown to the dentist, Mr L developed problems associated with an oroantral communication (OAC). Mr L did not return to the practice and obtained further treatment elsewhere. This denied the dentist the opportunity to discuss this complication with Mr L and to resolve any potential concerns at an early stage.

Mr L's lawyer claimed their client was not warned of the risks of developing an OAC and that he should have been referred to see a specialist. The dentist suggested that it was his normal practice to tell patients of such

risks; however, neither he nor his team could remember if a discussion had taken place on this specific occasion, and he had not recorded any warnings in the records.

The records and radiographs were examined by one of Dental Protection's experts and, despite all efforts to assist the dentist in defending the case, the lack of documentation made the case difficult to defend.


In court, the lack of appropriate records meant that it was the patient's word against the dentist's – and there is a real risk of a judge preferring the patient's oral evidence. Good record keeping is an example of good care, so inadequate records could create an impression of poor care, extending to the consent process.

LEARNING POINTS

- If there is a lack of documentation that warnings had been given to the patient, in a dispute it becomes the patient's word against the dentist's and the patient will often have greater credibility. It is therefore imperative to record the details of the specific warnings given.
- We have a legal and ethical obligation to disclose risks to patients and to keep comprehensive records. Without adequate records being made of patients being warned about possible treatment outcomes, it is very difficult to provide a robust defence against a claim or Dental Council investigation, as this case illustrates.
- A dentist could be tempted to alter or add to a patient's record should they become aware that the record is to be scrutinised. With modern technology such changes are easily recognised, and the courts and dental registration bodies take an extremely serious view of non-contemporaneous records being submitted as originals in evidence.

Case study

Leaving a sour taste in the mouth



Associate dentists leave their current practice for a variety of reasons, and occasionally this can be due to a breakdown in communication and issues surrounding working relationships within the practice. When an associate leaves a practice on bad terms this can be the catalyst for a burst of patient complaints. This scenario can be exacerbated if there is no agreement in place with the practice principal in relation to how to manage remedial treatment.

It is common practice for an agreed sum of money to be withheld by the principal for an agreed period of time when an associate leaves a practice, to allow minor problems to be resolved.

CASE STUDY

The relationship between a principal and an associate had deteriorated to such an extent that the associate had left the practice.

The associate was clinically very competent and experienced, and had completed a number of challenging ‘tooth wear’ cases.

One particular patient, Mr L, had been treated with composite build up restorations on numerous teeth to conservatively address his tooth wear and the finished result was satisfactory. Whilst the associate’s clinical records reflected the merits and limitations of composite resin versus porcelain restorations, there was no mention that further charges would apply for the maintenance and/or repair of these restorations.

When Mr L required some fairly minimal general polishing of the composite restorations due to surface staining, he said he had not been informed that additional charges would apply and did not expect the owner of the practice to charge him for this treatment.

Mr L became upset when asked to pay for polishing the composites and raised the issue with the principal, who passed the complaint to his former associate. The associate offered to review the patient and provide the necessary treatment at no cost, but the patient was unwilling to travel to see him.

This scenario was not an isolated example; it was a recurring story involving a number of patients who required similar maintenance work. Rather than completing this work as a gesture of goodwill to maintain the reputation of the practice, the principal encouraged every minor concern to develop into a complaint that required a formal response from the associate. The fact that the patients were being charged an over-inflated cost for maintenance treatment by the principal only added to the patients’ dissatisfaction.

The associate contacted Dental Protection and, with the benefit of hindsight, realised that he had not made it clear to Mr L – or to the other patients – that ongoing maintenance would be chargeable. He recognised that there had been no clarity regarding what aspects of the treatment were covered by the original fee and, as a result, patients had made their own assumptions.

Dental Protection advised the associate to talk to the principal and to try and come to an agreement, to avoid further incidents that could be harmful to both their reputations.

The associate and principal reached an agreement between them to cover the reasonable cost of post-treatment maintenance/polish appointments.

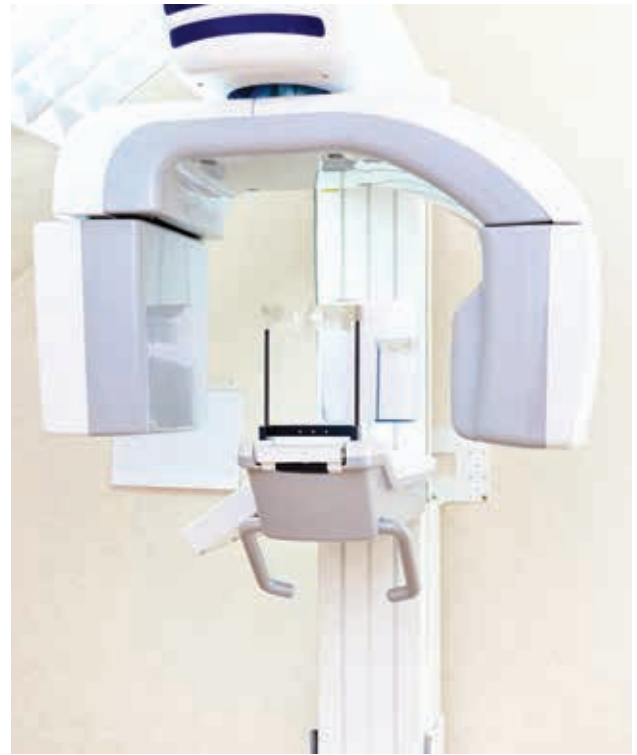LEARNING POINTS

- This case study demonstrates the importance of clear records and how beneficial it is to maintain a good relationship with colleagues.
- There should be a signed associate agreement that includes a clause regarding the retention of fees for remedial work when an associate leaves a practice. This avoids disputes and disagreements that may arise after the departure of an associate. These disputes are exaggerated where the working relationship has soured.
- When a dentist leaves a practice, inevitably there has to be a point where any further treatment provided by a subsequent clinician becomes chargeable. When planning treatment that which requires ongoing maintenance, clear explanations should be given to the patient and documented in the record. This should include an explicit statement as to what the initial fee includes and what charges may apply in the future. This should be set out clearly in writing for the patient and a copy retained in the records so everyone knows what to expect. If there are any queries after an associate has left, the principal and the new dentist have the necessary documentation to support future interventions and related charges.
- Financial disputes between the principal and an associate should be resolved between the two parties and not involve the patient. This aspect should be a ‘back office’ function and disputes should not be played out in front of the patient.

Case study

Considering CBCT

One of the most spectacular examples of new technology in modern dentistry is the increasing use of cone beam computed tomography (CBCT). Dentolegal consultant Jim Lafferty looks at the technique's potential pitfalls and key risks



©nakleyschikova/Gettyimages.co.uk

The improvements in assessment, diagnosis and treatment planning that come with the use of CBCT are well known – in the fields of implant placement and third molar surgery we have seen significant uptake, and our endodontic specialist colleagues are now also seeing the benefits of using it and how it can improve results for patients.

The use of such technology to improve patient care and reduce risk will be an attractive proposition to all involved, but there are potential pitfalls – awareness of these is vital, particularly given the high costs associated with purchases of this type.

There is a considerably higher exposure to ionising radiation that increases the risk of developing a malignancy, so we should all be able to justify why any CBCT is being used, even if you are prescribing the imaging to be taken elsewhere. In some jurisdictions there is now a legal requirement to record this justification in writing. Members in those territories report that this means they are more careful to consider both the benefits and the risks associated with CBCT and, as a result, have reduced the number of CBCT images that they take, reducing the amount of exposure to ionising radiation.

If you are responsible for assessing the resulting image you should ensure that you can demonstrate that you have suitable training for this and make a written record of the assessment. There are enormous amounts of information to be gleaned from these x-rays, and the person reviewing the slices has the responsibility to check for pathology in all those slices – even at sites distant to the area of interest.

In the accompanying case report, you will see that it is very important to establish who will be reporting on the image.

The key points dentists should consider in the area of CBCT are:

- Arrangements – who will be responsible for reporting?
- Assess – a CBCT without clinical examination is very difficult to defend.
- Balance – the risks of ionising radiation against the clinical information gained.
- Minimise – can the same information be obtained with a lower dose x-ray?
- Justification – record in writing the reason for taking the x-ray.
- Report – there should be a written report, leading to the normal recording of diagnosis, treatment options discussion, risk discussion, treatment planning and consent.

CASE STUDY

Mr D was referred to an oral surgeon for pain related to his temporomandibular joint (TMJ) issues. During the early assessments, a CBCT was prescribed, carried out in a remote CBCT and imaging centre, with a specialist radiologist report ordered. Over a year later, a further CBCT was ordered from the same centre when symptoms had spread.

The patient went on to develop a cancerous neuroma in his tongue, which by now had spread into the lymph nodes, and was considered inoperable.

The family complained to the regulator, and the oral surgeon contacted Dental Protection. He was particularly concerned, as his records of the patient's treatment were somewhat brief and generally of a low standard; however, with assistance from Dental Protection the member was able to show that he had ordered specialist reports, and that the developing neuroma had been missed in the original scan. It was put forward that the responsibility for failing to diagnose the tumour was not the oral surgeon's. We then worked closely with the member on developing a CPD programme around record keeping, so that by the time of the hearing, he was able to demonstrate that he had shown insight and taken steps to remediate.

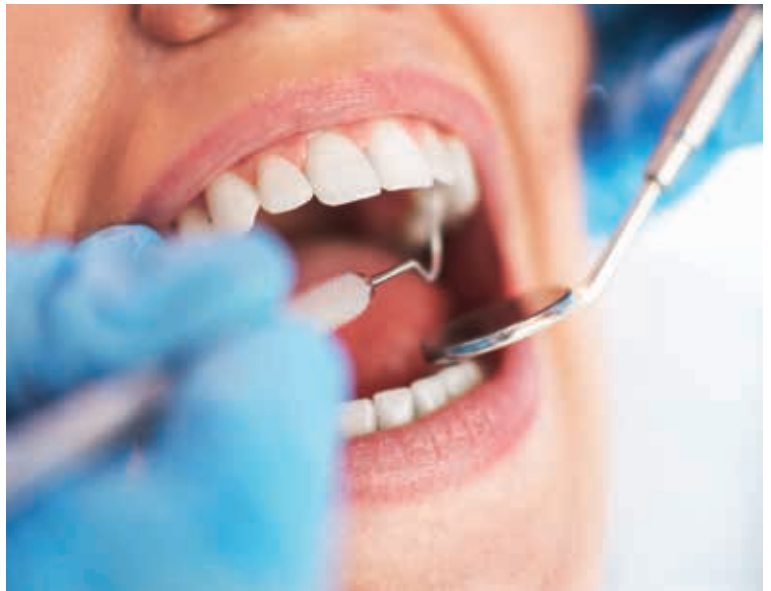Naturally the member was keen to emphasise in his response to the Dental Council how distraught he was at hearing the news, but he did not consider the complaint showed any wrongdoing on his part. This was recognised by the Dental Council and the case was dismissed.

LEARNING POINTS

- By having the image reported on by an appropriate specialist, the responsibility for spotting pathology outside the area of interest is not the dentist's.
- All x-rays should have a written report.

Case study

An unexpected surprise



Ms C visited her dentist, requesting an improvement on her overall smile and the specific appearance of the upper lateral incisors. They had been restored with porcelain veneers some years previously and the colour match with the natural adjacent teeth was now unsatisfactory.

Ms C, an aspiring actress currently living overseas, had been regularly attending this particular dentist since childhood. The dentist had placed the existing veneers more than 12 years ago as she had peg-shaped lateral incisors. At a previous visit Ms C had obtained some home tooth whitening gels that she had been using, and the veneers were now a good few shades darker than the rest of her teeth.

She told the dentist she wanted all of her teeth to be a uniform, very light colour. When the dentist removed the existing veneers he noted the underlying vital tooth structure was particularly dark, suggesting there had been some longstanding bond failure. He had recently treated a patient with a similar problem, and so was acutely aware of how challenging it was to replace veneers on a like-for-like basis and create the aesthetic outcome the patient desired.

He therefore made a decision to provide a full coverage zirconium crown on each lateral incisor. For some reason – possibly because he was overloaded with distractions at the fit appointment and was running late – he failed to check the contact point distally at 22 and had not noticed that this crown did not sit correctly. Ms C returned a few days later complaining of sensitivity and a deficient margin palatally that she could feel with her fingernail. It was agreed that this crown would be replaced; however, it became impossible for an appointment to be scheduled due to the patient's overseas commitments.

The sensitivity continued, so Ms C obtained a second opinion and was advised that both crowns had not been fitted correctly. The report from the new dentist was supported by radiographic evidence confirming a substandard marginal fit – which explained the sensitivity reported. The crowns were replaced by the new dentist and a letter of complaint was sent to the original dentist from the patient. She clearly felt that she had been more involved in the latest treatment decision than she had been when the zirconium crowns had been discussed, stating that she had not been fully informed about how much of the additional tooth would be sacrificed in order to accommodate the crowns, and what impact this might have long-term. She did not reference the fact that the dentist had been willing to rectify the situation, and that it had been her own scheduling difficulties that had caused the problem to remain unresolved.

The dentist contacted Dental Protection for advice and assistance on how he might manage the complaint, as Ms C was now seeking a refund of his fees and a payment covering the cost of her remedial treatment. Notwithstanding his offer to replace his faulty work, he felt it was unfair that he should be expected to finance the remedial treatment as well. Having lost the trust of the patient, the dentist lost the chance to recover the situation, particularly where there was factual evidence of a poor fit. He also accepted that the consent process had been undermined by his failure to identify how much information the patient needed, specifically around the long-term risks attached to a more aggressive tooth preparation compared with a like-for-like replacement of two veneers.

In her complaint, the patient stated that had the correct information been given at the time she had the veneers replaced, she would have made a different decision.

Our advice to the member was that a refund of his treatment fees would not be sufficient to resolve this matter, so we made a contribution towards the additional costs of the remedial treatment.

LEARNING POINTS

- The law on consent provides a framework that protects patients' rights to make an informed decision about all aspects of their treatment. In this case, the choice of zirconium crowns instead of veneers was not adequately discussed, nor was there anything in the records that we could use to defend the dentist's position. Had the patient obtained legal advice, she would have been told of her right to compensation and it made no sense to allow this situation to escalate, where legal fees would dwarf the cost of paying for the remedial treatment.
- Unlike a tightly-worded contract of insurance that may only respond to a claim, the use of discretion means that in some situations we can proactively manage a case by providing financial assistance towards the remedial treatment. In doing so, we protected the interests of the member and his reputation. We also protect the mutual fund and the interests of the wider membership by containing unnecessary legal costs.

Dental
Protection



HERE TO PROTECT YOU AND YOUR PROFESSIONAL REPUTATION

Learn how to manage your risk
and improve patient safety

Our **FREE** risk prevention tools and
techniques include:

- Online learning
- Lectures and seminars
- Workshops

REGISTER TODAY AT
DENTALPROTECTION.ORG/PRISM

Find us on   @MPS_Dental

CONTACTS

You can contact Dental Protection
for assistance via the website
dentalprotection.org

Membership

Contact us via the SDA
6258 9525

Or you can speak to an adviser in the UK between 08.00 and
18.30 Monday to Friday (GMT)

Phone +44 113 241 0533
membership@sda.org.sg

Dentolegal advice

Contact us via the SDA
6258 9252

Or you can speak to a dentolegal adviser in the UK, between 08.30 and
17.30 Monday to Friday (GMT)

Phone +44 207 399 1400

dental.asia@dentalprotection.org

Opinions expressed by any named external authors herein remain those of the author and do not necessarily represent the views of Dental Protection. Pictures should not be relied upon as accurate representations of clinical situations.

Dental Protection Limited is registered in England (No. 2374160) and is a wholly owned subsidiary of The Medical Protection Society Limited ("MPS") which is registered in England (No. 00036142). Both companies use 'Dental Protection' as a trading name and have their registered office at Level 19, The Shard, 32 London Bridge Street, London, SE1 9SG.

Dental Protection Limited serves and supports the dental members of MPS with access to the full range of benefits of membership, which are all discretionary, and set out in MPS's Memorandum and Articles of Association. MPS is not an insurance company. Dental Protection® is a registered trademark of MPS.