




RISKWISE

ISSUE 20 | JUNE 2019

CARIBBEAN AND BERMUDA



The core of consent

Why a patient's signature on a form does not automatically mean consent

Iatrogenic injuries

What can be done to avoid them

Case studies

Practical guidance and learning from real life scenarios



Editorial



DR NANCY BOODHOO

HEAD OF MEDICAL AND DENTAL SERVICES, CARIBBEAN AND BERMUDA

WELCOME TO THE NEWEST ISSUE OF *RISKWISE*. WE HAVE LISTENED TO YOUR CONCERNS AND THE AREAS IN WHICH YOU HAVE EXPERIENCED DIFFICULTIES IN YOUR LOCAL PRACTICE AND COVERED SOME OF THESE TOPICS IN THIS EDITION.

Good ethical practice, maintaining high standards and good communication with other members of the team will always put you in a good position to practise safely. I am sure you are familiar with these points but sometimes reading about other members experiencing them in a particular scenario can help to highlight what could, or should, be done.

Our case report “Is it vital?” shows how good communication and time spent with patients during an examination can help to prevent problems later on. It highlights how important it is to make patients aware of their present condition and the probability of future problems should treatment not take place. When this is discussed with the patient and written in their notes, there can be no confusion as to whether the patient was made aware of the situation and the necessity for treatment. This is particularly important in times of economic hardship, when limited funds could mean dental treatment is delayed. When things go wrong it is so easy to blame someone else.

“Leaving a sour taste in the mouth” is as relevant today as ever before. Any of us who have worked in general practice, whether as a principal or an associate, will be familiar with the scenario that often arises when a dentist leaves a practice. There will be patients who may require some remedial work and/or follow up care and additional treatment – this is not necessarily due to any failure on the part of the departing dentist. Complications and further treatment needs can arise at any time. Examples include the fracture of a cusp, where a large restoration has been provided, or irreversible pulpitis

resulting from the placement of a deep restoration. Maintaining a professional relationship built on trust and mutual respect can often defuse the threat of patient dissatisfaction and help to avoid further problems and complaints.

“Protecting your reputation” is very pertinent in today’s world, where social media is the platform for people to keep in touch with each other. In this case, the patient’s mother writes a negative Google review and sends threatening emails to the dentist. Unfortunately we have no control over what patients choose to put on social media about us. This is an area that is growing and changing, and our experts at Dental Protection are here to advise and help you if you find yourself in this difficult situation.

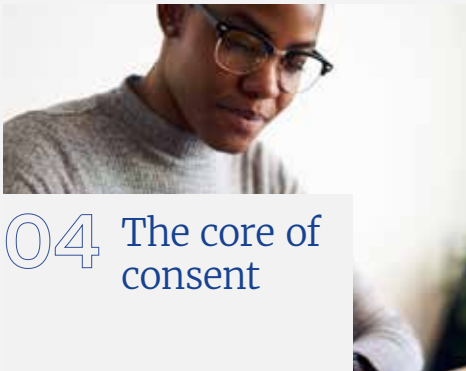“Short term orthodontics” is very relevant as more and more general practitioners undertake orthodontic procedures with clear aligners. Careful case selection and evaluation is probably the most important learning in this type of treatment. It is very easy to feel confident in your ability to undertake this treatment but it is when the treatment goes wrong or does not come up to the patient’s expectations that your lack of experience could be criticised, giving rise to a complaint from the patient.

I hope you will find this edition of *Riskwise* interesting and helpful. If there is a topic that’s specifically of interest to you, that you would like us to include in the articles, please get in touch. We always welcome your comments and look forward to your participation.

With good wishes

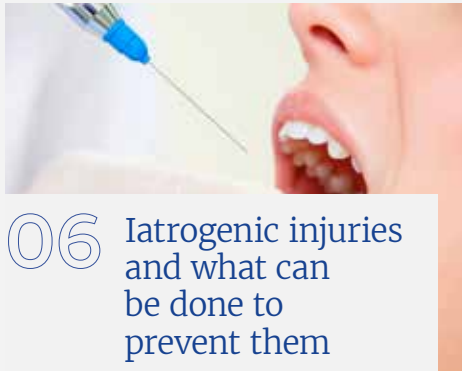Dr Nancy Boodhoo BDS FDSRCS FFFLM
Head of Medical and Dental Services, Caribbean and Bermuda

Contents



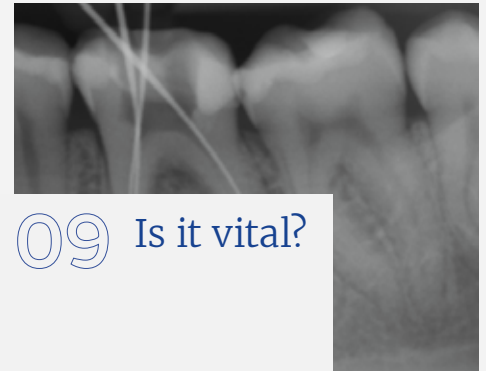04 The core of consent

When has a patient agreed to a treatment?



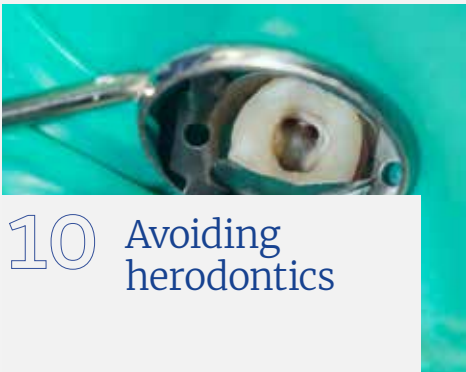06 Iatrogenic injuries and what can be done to prevent them

Wherever you are in the world, there is generally a legal obligation in place that sets out the duties of employers to ensure appropriate standards of quality and safety in a dental practice.



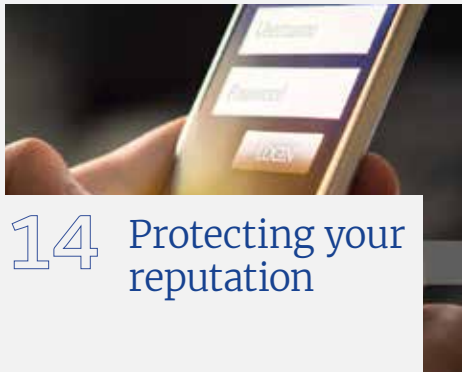09 Is it vital?

Carrying out a thorough assessment of a patient's oral health.



10 Avoiding herodontics

Managing unrealistic expectations from the outset.



14 Protecting your reputation

Monitoring comments on social media platforms.

Editor

Anna Francis

Design

Conor Walsh

Print

Spellman Walker

Production

Emma Senior

Contributors

Simrit Ryatt

Louise Eggleton

Joe Ingham

The core of consent

There is a common misconception that if a patient puts their signature to a 'consent form' that they have automatically agreed to the proposed treatment. This could not be further from the truth, and **Dr Joe Ingham**, dentolegal consultant, explains why

"Every human being of adult years and sound mind has a right to determine what shall be done with his own body; and a surgeon who performs an operation without his patient's consent commits an assault for which he is liable in damages. This is true except in cases of emergency, where the patient is unconscious and where it is necessary to operate before their consent can be obtained."

This was the judgement of Benjamin Cardozo in the case of *Mary Schloendorff v the Society of New York Hospital* in 1914. The patient was admitted to New York Hospital and consented to being examined to determine if a diagnosed tumour was malignant. However, she withheld consent for removal of the tumour. The doctor examined the tumour, found it malignant, and then disregarded the patient's wishes and removed it. The court found that the operation to which the plaintiff did not consent constituted medical battery.¹

THE PROCESS

It is important to realise that consent is a process and not a one-off event. Treatment plans often change mid-course. This is more likely to happen if the proposed treatment is extensive and complex. A tooth that had originally been planned for root canal treatment may, once treatment is embarked upon, be found to have sclerosed canals, rendering it unsuitable for the proposed endodontic procedure.

It would not be appropriate to simply go ahead and extract the tooth without first discussing this with the patient. This stands even if extraction is the only reasonable alternative and in the patient's best interests.

Failure to revisit the consent process could place the dentist in the same position as the surgeon who removed Mary Schloendorff's tumour back in 1914. The patient could claim that they had been assaulted and seek compensation.

The absence of detailed clinical records is often a major obstacle in defending a dentist against a claim in negligence. It is important that a record of discussions that have taken place with the patient, with regards to the consent process, are made.

THE DEFINITION

A reasonable definition of consent is: "The voluntary and continuing permission of the patient to receive a particular treatment. It must be based upon adequate knowledge of the purpose, nature and likely effects and risks of that treatment, including the likelihood of its success and any alternatives to it."

Touching another person without permission is the definition of battery, so the patient's consent is a necessary step prior to starting any treatment. A patient who willingly enters the surgery, lies down on the chair and opens their mouth can reasonably be assumed to have consented to a dental examination. This is referred to as implied consent.

Dentists and patients should work together through a process of supported decision-making, with the dentist providing the information the patient requires to make a decision and ensuring that the patient has understood the details and implications of what is involved. This includes any fees that may be charged.

Remember that consent is not a transitive verb: it is not something that a clinician does to a patient.

"I consented the patient for surgical extraction" is factually and grammatically incorrect.

"I obtained the patient's consent for the surgical extraction" is a more appropriate statement.

An individual has a right to self-determination and consequently only if they have capacity to make that decision. A wife, for example, cannot give consent for her husband's treatment irrespective of how well intentioned the attempt may be!

However, if the individual lacks capacity then their next of kin or the person who has power of attorney for decisions on their health can make that decision in their best interests.

THE VALIDITY

There are three components to valid consent:

1. Information

The patient must be in possession of sufficient information to make an informed decision.

2. Capacity

He/she must be able to understand that information and weigh it in the balance to make a decision.

3. Autonomy

The patient must be free from duress from the dentist.





INFORMATION

The question is: 'How much information does a patient need to have to enable them to give full informed consent?'

There are some patients who, when presented with treatment options, simply lie back in the chair and say 'you are the expert – you decide!' Whilst this may be taken as a welcome validation of the trust the patient places in you, pursuing the 'doctor knows best' route can be fraught with difficulty.

The amount of information in relation to dental treatment that a patient has access to, especially on the internet, is overwhelming. This has generated increasing numbers of patients who attend consultations with preconceived ideas about exactly what type of treatment they are prepared to accept. It goes without saying that the consent process for these individuals needs to be particularly robust and more time should be spent explaining all options.

When discussing options for treatment, these must always be compared with the option of not receiving any treatment. Patients should be given the relevant information to make a decision as to whether they wish to undergo any available treatment or allow the condition to remain untreated.

CAPACITY

Unless there are good reasons to believe otherwise, it is assumed that adult patients are competent to make decisions about their treatment themselves. This includes the assumption that they have the capacity to give or withhold their consent to dental treatment.



Dentists and patients should work together through a process of supported decision-making

Patients cannot be automatically considered lacking in capacity just because they do not agree with a recommendation made by the dentist. For the purposes of consent to treatment, capacity is both decision-specific and time-specific. It refers to the patient's ability to make the specific decision at the relevant time at which it is made and for the particular treatment in question. Because of this, the person who assesses capacity is the dentist providing treatment and not a mental health expert.

AUTONOMY

All patients should be treated as individuals and assisted in making decisions. Consideration should be given in respect of their own beliefs and values. Remember that a patient is allowed to make an unwise decision about their treatment. In the event that an upper incisor needs a crown the patient may opt for gold rather than porcelain. The fact that the treating clinician, if they were the patient, would not choose that option should not be a factor.

MINORS

The consent process for treatment involving children presents its own difficulties both from a capacity and authority perspective. Providing they are capable of understanding

what is proposed, and of expressing their own wishes, minors should be regarded as having the capacity to consent to dental treatment.

Much will obviously rest on what is being proposed. For example, a child may be competent to consent to a check-up with few ramifications, but may lack the capacity to understand the complexities of orthodontic treatment involving extractions that may have profound implications for their future wellbeing and appearance. Generally speaking, only the child's parents are able to provide consent.

Grandparents, siblings and child-minders do not have the necessary authority to give consent. There may be instances where the parental responsibility has been transferred by the courts from the biological parents to someone else. In these situations it is prudent to ask to see any relevant paperwork in order to verify the validity of the claim.

In an emergency situation it may be necessary to make a decision about the treatment for a child without the consent of the parent/guardian, but acting in the child's best interest. For example, it may be inappropriate to delay the replantation of an avulsed incisor, where time is of the essence, if those with parental responsibility cannot be reached.



REFERENCES

1. Basic right to consent to medical care - Schoendorff v. Society of New York Hosp., 105 N.E. 92, 93 (N.Y. 1914). Biotech.law.lsu.edu.2019. <https://biotech.law.lsu.edu/cases/consent/schoendorff.htm> (accessed 13 Mar 2019).



Iatrogenic injuries and what can be done to avoid them

Wherever you are in the world, there is generally a legal obligation in place that sets out duties of employers to ensure appropriate standards of quality and safety in a dental practice. Simrit Ryatt dentolegal consultant, looks into some iatrogenic injuries and what can be done to avoid them

This legal obligation can include a delegable duty to team members to make sure equipment used in treatment is safe and maintained to be in good working condition in accordance with manufacturers' instructions. It is nevertheless important to emphasise that it remains the responsibility of the clinician who is handling a piece of equipment to ensure a patient is not inadvertently harmed, either by operator carelessness or equipment malfunction.

Experience is generally a good thing, as you become more comfortable with dealing with challenging situations throughout your working day. It is also worth bearing in mind that an experienced clinician may subconsciously become complacent about the risk attached to hazards in a dental

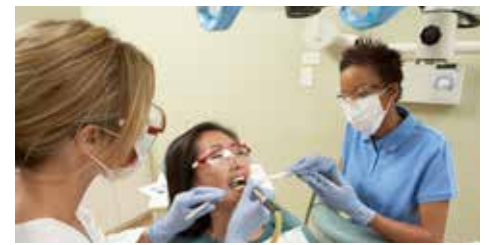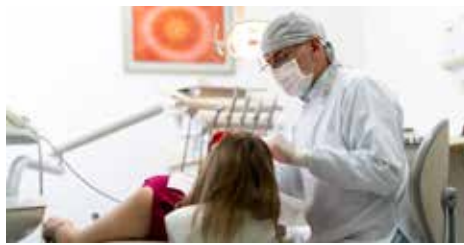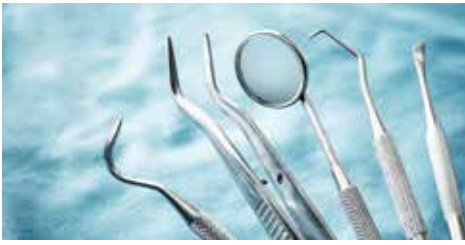surgery, particularly where the risk has been identified but not corrected for a while.

No matter how proficient you are, there are some scenarios that are impossible to predict and are not under your direct control, such as sudden movements or the behaviour of a patient. In light of this, it is important that we manage risk by focussing on the variables that we can control, by ensuring that a regular risk assessment of the surgery equipment and operative procedures is carried out.

A good example of how this may be put into practice is to plan procedures in advance and adopt a checklist approach to ensure that the required materials and equipment are readily available and on-hand.

It goes without saying that personal protective equipment at work should protect both the members of the dental team and patients. All members of the dental team play a part in identifying hazards and risks and reporting them before they cause injury. Risk assessment and reporting should be discussed at team meetings and follow-up actions should be notified to all team members. It is also important to keep a record of these discussions for future reference.

To help your understanding of how incidents can occur, we have looked at some examples from our case library. We have also highlighted the learning opportunities each incident provides.



CASE STUDY – A LACERATION FOLLOWING AN EXTRACTION

Mr D attended the dentist and during his examination he expressed his wish to have dental implants to restore the existing space he had from the extraction of teeth 45 and 46 around 20 years previously. The dentist also noted that tooth 47 had fractured beyond repair. The patient otherwise had maintained a good standard of oral health.

HOW DID THE ACCIDENT HAPPEN?

At a subsequent appointment, the dentist was using a luxator around tooth 47 that slipped and lacerated the adjacent soft tissues. The laceration on the inside of the cheek was severe and extensive.

HOW WAS THIS MANAGED?

The dentist explained what had happened to the patient and offered an immediate apology. The area was sutured and a review appointment was arranged for the following day. The patient was contacted by telephone later in the evening and he explained he was in some discomfort and was aware of some swelling in the area of the wound.

AT THE REVIEW APPOINTMENT

At the review appointment the wound was assessed and the swelling noted. As the injury had been caused by an error in technique, the risk of this type of injury had not been discussed.

The patient subsequently had to take a week off from work and advised the dentist of his intention to claim for compensation for his pain, suffering and loss of earnings.

The dentist called Dental Protection and our team was able to negotiate an early and appropriate settlement, protecting the member's position and avoiding any risk of escalation.

LEARNING POINT

- Although the dentist was very experienced, the error was attributed to a lapse of concentration that had unfortunate consequences. On reflection, the dentist realised perhaps his access to the area could have been improved and his finger rests more stable and sturdy. His reflection and subsequent analysis was recorded and shared with the rest of the team in the expectation that a similar situation may be prevented in the future.

CASE STUDY – A CHEMICAL BURN

Miss C attended a surgery complaining of discomfort at tooth 27 following a dislodged restoration. A radiograph was taken, that showed that the distal-occlusal cavity was in close proximity to the dental pulp and that there was caries present. Miss C was made aware of the radiographic and clinical findings and informed that root canal treatment may be indicated.

As anticipated, during the process of excavating caries, the pulp was exposed and the first stage of endodontic treatment was carried out. During irrigation of the root canal system, the irrigation syringe tip detached from the body of the syringe and a small volume of sodium hypochlorite splashed over the patient's face. Miss C was advised to immediately rinse her face, and the initial stage of the endodontic treatment was completed.

At the subsequent appointment Miss C reported some soreness in the area affected by the hypochlorite. The dentist completed the endodontic treatment and was satisfied with the postoperative result. The patient complained and requested compensation for the adverse incident and threatened to escalate her concerns to a lawyer.

After seeking advice from Dental Protection, it was agreed that the treatment fees should be waived and a contribution was made by Dental Protection towards the cost of treatment provided by a specialist dermatologist.

LEARNING POINTS

- Reflecting upon his treatment, and with the benefit of hindsight, the dentist acknowledged he should have used a rubber dam. The dentist always found accessing the tooth easier without a rubber dam and would generally place it after gaining access. He did not routinely apply a rubber dam at emergency appointments, and the incident reminded him of the need to do so in future.
- Always ensure that the irrigation needle is fully engaged on the body of the syringe and avoid excessive force during the irrigation process.

CASE STUDY – A BURN INJURY TO THE LIP AND CHEEK DURING AN EXTRACTION

During a surgical procedure under sedation, a dentist caused an accidental injury to the lip and cheek of Ms W. The surgical procedure involved making gingival incisions, raising a flap and trimming away bone to remove a partially erupted 48. During the procedure, the right cheek mucosa was burnt by contact with an electro-surgery tip that was being used to trim some soft tissue.

HOW WAS THE SITUATION MANAGED?

The wound was carefully cleansed and closed with sutures.

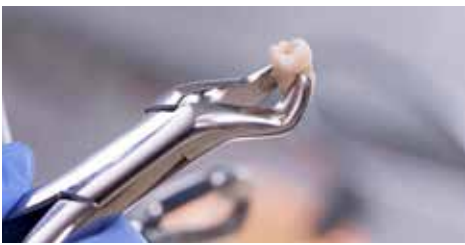The fiancé of the 35-year-old patient joined her in the recovery room, and although they accepted the explanation at the time, they called later that evening to complain.

A month later the wound had healed fairly well, but there was a residual indentation remaining that was quite apparent. Ms W was concerned the indentation would be present in four months' time, when she was due to get married. The dentist and his clinic agreed to arrange treatment for her with a plastic surgeon and they were informed there was a good chance the wound would heal completely with minor surgery.

Ms W went on to claim for compensation. Although the dentist had expressed his regret at what had happened and arranged for further specialist care, there was still an expectation that the exercise of a reasonable standard of care would have meant that such an injury would not have occurred.

LEARNING POINT

- A team meeting was held following the incident and everyone acknowledged how potentially easy it was to cause such an injury, especially when patients have been locally anaesthetised and also sedated. In recognising the risk, the team were in a position to avoid future occurrences.



CASE STUDY – CRUSH INJURY

Mr K was booked in for a routine extraction of tooth 27, which had been causing discomfort and was unrestorable. A mesial-occlusal restoration was planned for 36 at the same appointment.

The dentist completed a composite filling in 36 and then set about extracting the 27. The procedure took longer than expected, but eventually the tooth was extracted in one piece.

Following the extraction, the dentist noticed Mr K had developed some bruising around the lower lip which had been caused by the forceps or elevator trapping the soft tissue. The dentist had not noticed this at the time, presumably because of his focus on the challenge of the extraction itself, and being under some stress knowing that a number of other patients were waiting to see him and that he was now running very late.

HOW WAS THE SITUATION MANAGED?

The dentist immediately apologised and also contacted Mr K later on that day. As Mr K was grateful to have had the problematic tooth extracted, he did not take the matter further and accepted the apology.

LEARNING POINTS

- The dentist acknowledged that he had been so focussed on the challenging 27 extraction that he had forgotten the lower lip was also anaesthetised. As they were understaffed, he had been sharing a nurse with another clinician, whereas usually he would have had a nurse on-hand to notice an event such as this. At the next practice meeting this incident was discussed and it was agreed the dentist should always be supported by a dental nurse when carrying out extractions and also to be mindful of the risk of soft tissue injuries to anaesthetised areas.
- Complications always seem to occur when there is time pressure. There should be protocols in place for managing such situations. In this case, a collective team-led decision was made that should a dentist run particularly late, patients would be advised of the delay and given the option to rearrange their appointments or be seen by another dentist if possible.

Images left to right:
© alexisdco@gettyimages.co.uk, Keith Brofsky@gettyimages.co.uk,
FG Trade@gettyimages.co.uk

CASE STUDY – MECHANICAL INJURIES

A newly qualified dentist mentioned to her principal that the fixation plate that attached the x-ray machine to the wall was not stable and when the arm was fully extended, the pressure on the plate caused some movement. The machine was wall-mounted to the left of the patient chair and had to be extended fully when taking radiographs on the right hand side. The arm was not stable at its full extension and would often drop after it had been aligned to expose the film. As a result, the final images were of limited diagnostic value as they did not capture the teeth and surrounding areas.

The young dentist asked for the fixation mechanism to be repaired or replaced. The principal resisted this and believed the dentist was over-reacting. He suggested an ‘alternative technique’ that he thought would remedy the problem. His solution was to forcibly wedge the collimator so it would sit next to the patient and the x-ray arm would not slip down.

The dentist called Dental Protection and a dentolegal consultant suggested the member put her concerns in writing to the principal. It was suggested her concerns could be justified by carrying out a risk assessment of the situation to identify what issues could arise and what harm could flow from a potential incident. It was also pointed out that should the dentist believe the working environment was hazardous, as she was controlling the handling of the equipment, it would be her responsibility to ensure it was safe.

Before the dentist could consider the advice further, she realised her next patient was due and required a radiograph. Unfortunately, the x-ray machine fell off the wall and took the surgery chair-light down with it, striking the patient on the head.

HOW WAS THE SITUATION MANAGED?

The patient was able to have the x-ray in the next room and the principal immediately set about arranging for the x-ray machine and surgery chair-light to be repaired.

LEARNING POINT

- The principal recognised he should have immediately addressed the situation. The patient was not injured but was unsettled, and the practice called later on that day to ensure they were alright.

SUMMARY

These case studies highlight the importance of team work, learning from mistakes and how risk awareness can reduce the number of injuries that are often avoidable.

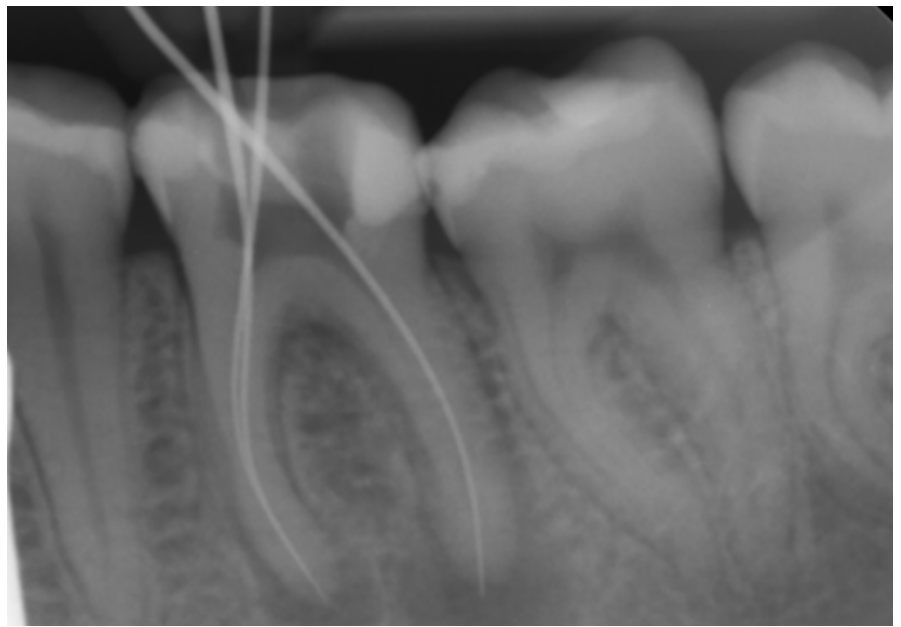
Where risks can be avoided, such as the placement of a well-fitting rubber dam for all endodontic procedures, it is surprising why anyone would risk not doing so. Similarly, when equipment is well maintained this reduces the risk to staff and patients.

These examples demonstrate the value of a sincere and sympathetic apology and the importance of professional support. Although some patient safety incidents may require additional help in order to resolve the situation to the patient’s satisfaction, a telephone call following an incident can go a long way to convey care and indicate genuine concern, and can help reduce the chance of a patient taking matters further.

Whether it is in the form of professional advice, help with writing a response to a patient or assistance with arranging formal compensation, Dental Protection is here to protect the careers and reputations of members.

Case Study

Is it vital?



M r R attended a practice as a new patient. He reported no symptoms although during the examination the dentist noted the large composite restoration at 36, which had a small fracture to one side. The dentist promptly repaired the fracture with composite and placed a note on the clinical records to monitor the tooth.

Mr R returned six weeks later complaining of pain and swelling on the lower left side of the mandible. The dentist suspected periapical periodontitis at 36 and the diagnosis was confirmed by the periapical radiograph, which clearly showed pathology at the root apices of the 36.

The somewhat unhappy patient was concerned that he would lose the tooth, but was reassured by the dentist that the tooth could be saved by carrying out root canal therapy, although she did also advise that extraction could still be an option.

The dentist extirpated the diseased pulp and a temporary dressing was placed. Mr R's symptoms resolved and he returned at a later date for the completion of the endodontic treatment.

The dentist had previously noted the curvature of the mesio-buccal root and suspected the canals may be sclerosed. She mentioned to the patient that the mesio-buccal root could therefore be difficult to navigate and could compromise the quality of the root canal treatment.

During the canal preparation phase of the treatment, a file fractured in the mesio-buccal canal. A radiograph confirmed that approximately 12mm of the file remained in the root and about 3mm of this was beyond the apex. The dentist was unable to retrieve the fractured file and informed the patient about what had happened.

She explained to the patient that instrument breakage was a recognised complication – particularly in curved roots. Mr R became upset when it was suggested that he would now need to see a specialist to complete the treatment. He left the surgery before the dentist could place a temporary restoration, saying that he no longer trusted her.

She did not hear anything further from Mr R, until she received a treatment plan and cost estimate from a specialist endodontist whom the patient had seen. A few days later, the dentist also received a letter from the regulator, notifying her of Mr R's complaint. The dentist immediately contacted Dental Protection for advice.

The discussion of the case with one of our dentolegal consultants was a good opportunity for the dentist to reflect on the incident. She realised that she could have undertaken further investigations prior to repairing the fractured composite – such as a vitality test, and if this was negative, considered a periapical radiograph to check for any periapical pathology. This would have revealed the existing pathology at 36, at which point discussions could have taken place with Mr R, potentially avoiding the symptoms experienced by the patient some weeks later.

The dentist also noted that she had not followed her normal routine of discussing all the risks of endodontic therapy with the patient. She had been eager to commence treatment given the patient's symptoms, and had cut short the conversation about the risk of instrument fracture in a sclerosed canal, meaning that she wasn't possibly as clear as she would have wished, and had also not offered a specialist referral.

The precipitating trigger for the complaint was the broken instrument, but the other predisposing factors also contributed to this outcome. The fractured file in isolation may not have incited such an uncompromising

response from the patient if he had been fully informed, and if the diagnosis had been made at the time of the initial examination appointment.

Dental Protection provided support and advice to the dentist throughout her case, and covered the costs of the remedial treatment with the specialist.

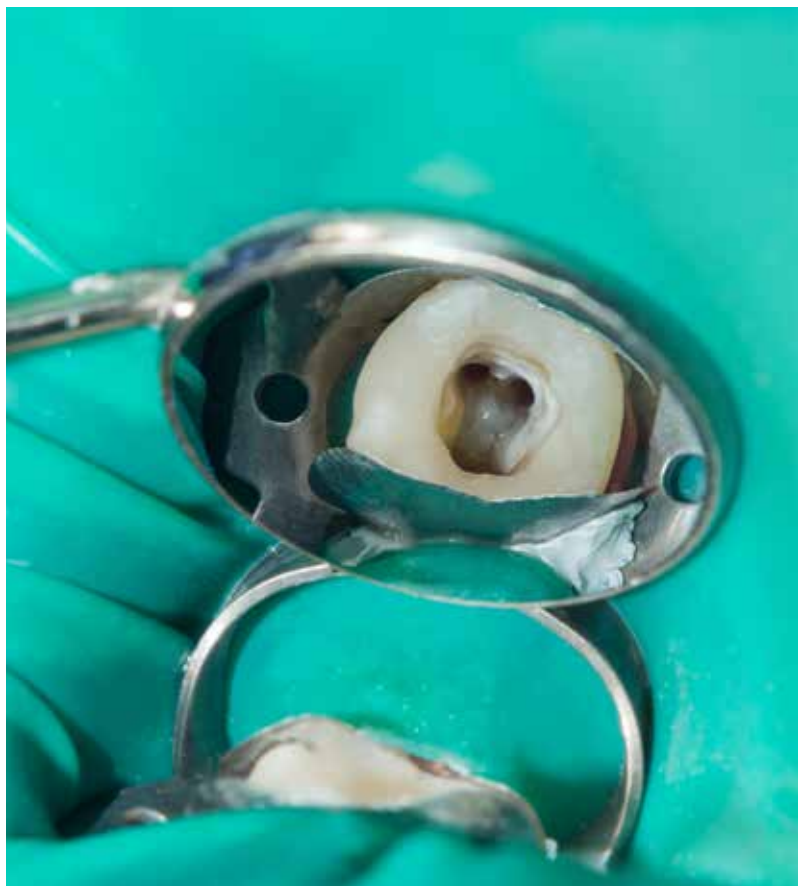With our advice and guidance, the dentist was able to demonstrate to the regulator that she had reflected on the case and had learned from the experience and applied that learning to her daily practice. This included clinical aspects of care, as well as consent and effective communication. As a result, the regulator took no action.

LEARNING POINTS

- **The dentist has a responsibility to carry out a thorough assessment of a patient's oral health at the time of the initial examination and prior to any treatment, including applying any special tests. In this case, vitality tests could have been carried out, which would likely have prevented the unfortunate sequence of events.**
- **Providing the patient with the necessary information – such as all treatment options available, along with the advantages/disadvantages, risks and consequences – enables the patient to make an informed decision over what approach they wish to take, and contributes to obtaining valid consent.**

Case Study

Avoiding heroic dentistry



Ms B was suffering from pain that kept her awake at night. An examination by the dentist established tooth 27 was the cause of discomfort. The 27 had extensive dental decay and a missing buccal wall. Ms B had an otherwise intact arch and was keen to save the tooth – she did not want a dental extraction.

The dentist explained that endodontic treatment carried no guarantee of success, especially with the extent of damage to the enamel walls, and extraction was offered as the only realistic alternative.

Ms B was quite persistent in her demands for root treatment, along with a full coverage crown, and was unwilling to be referred to a specialist. The dentist felt pressurised by the patient and embarked upon the endodontic treatment against her better judgement.

Five visits later, only two of the canals had been located and the third may have been perforated as it bled on instrumentation. This was discussed with Ms B and the tooth was dressed.

Whilst the endodontic treatment was becoming more complicated, Ms B was still unwilling to consider an extraction and was forceful in her request for the root treatment to be completed by the practitioner.

Further explanations were provided, but despite this Ms B remained convinced that a crown would solve the problem. She decided to visit a second dentist and was informed that the tooth had an incomplete root canal treatment.

The first dentist received a letter of complaint questioning why the endodontic treatment she had been completed in five visits and why had she been charged for this incomplete and unsuccessful treatment.

The dentist contacted Dental Protection for advice on how best to respond.

Whilst the clinical records were detailed, the practitioner was vulnerable in some areas regarding the clinical care provided. In terms of the pre-operative assessment, the restorability status of the tooth at the outset was questionable. During the procedure the dentist could not place a rubber dam because of insufficient residual coronal tissue, and owing to a lack of anatomical landmarks, a perforation occurred. With hindsight, the practitioner realised that the decision to carry out root canal therapy intervention had been a poor one, and she should not have attempted the procedure in the first place.

With Dental Protection's advice and assistance the complaint was resolved by refunding Ms B for the initial endodontic treatment and also contributing towards the cost of the second dentist's assessment.

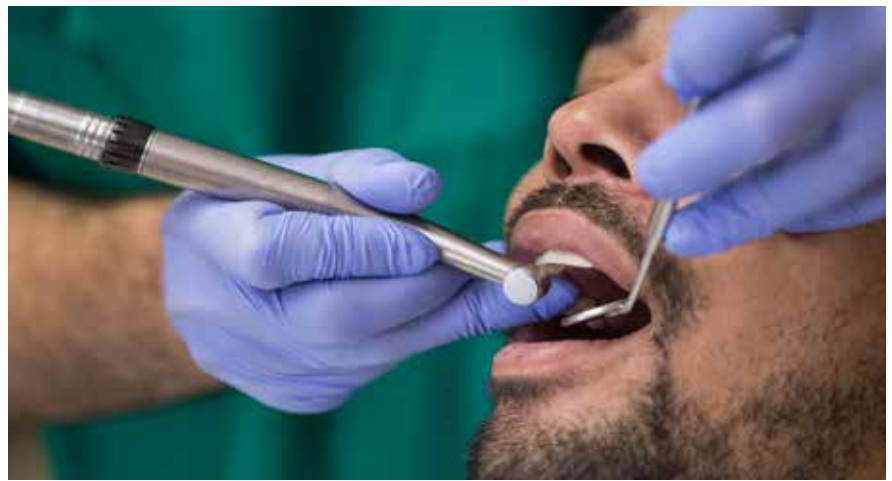Had Ms B pursued the matter with a claim for clinical negligence, the solicitors could potentially allege that Ms B had been subjected to an inappropriate procedure with associated pain and suffering.

LEARNING POINTS

- Be alert to patient-led dentistry and the demands of strong-willed patients. Unrealistic expectations should be identified and managed from the outset. The reasons why the treatment is inappropriate should be communicated effectively.
- Avoid being coaxed by persistent patients into carrying out treatments that have a slim to zero chance of success.
- Just because a patient consents to treatment, it doesn't necessarily mean that the treatment is appropriate.
- In this particular case, the complaint was resolved by a detailed letter of explanation and a refund of fees.
- In trying to appease the patient, the dentist had spent over three hours attempting treatment that was essentially doomed to fail, and then had to spend even more time managing the resulting complaint.
- This case highlights the dangers of attempting heroic dentistry; dentists are unlikely to be thanked for lack of success.
- Unrealistic expectations should be managed carefully from the outset.

Case Study

A foreseen fracture



©RobertDavid/Gettyimages.co.uk

Mr G attended an emergency appointment complaining of acute pain in his upper left quadrant. The dentist identified a carious cavity at tooth 26.

Having undertaken a thorough examination, including vitality testing and exposure of a periapical radiograph, a diagnosis of irreversible pulpitis was made. The dentist noted the curvature of a disto-buccal root which appeared from the radiograph to be in very close proximity to the floor of the maxillary sinus.

Mr G was keen to have this tooth extracted, and the dentist, mindful of her obligation to offer all treatment options, also discussed root canal therapy and suggested that given its complexity there was also the option of a referral to a specialist colleague.

Mr G was also informed of potential risks and complications of an extraction, and in particular, the possibility of a fracture of the curved portion of the disto-buccal root. The risk of a potential oral-antral communication and the possibility of the retained root being displaced into the maxillary sinus were also discussed. The usual general risks – such as bleeding, bruising and postoperative infection – were also explained, with the dentist using the radiograph to support his discussions so the patient had some visual imagery to help his understanding.

Although the dentist felt competent to extract the 26, she also considered extirpation of the pulp to relieve Mr G's symptoms, and, as she anticipated a challenging extraction, also discussed the option of a referral to a specialist oral surgeon. However, as Mr G was suffering from acute symptoms, the dentist felt that it was not unreasonable for her to attempt the extraction and given the circumstances, it was also an appropriate treatment option.

After taking a short time to consider all the information provided, Mr G requested the dentist to go ahead with the extraction. He signed a consent form that included information relating to the shape of the disto-buccal root and all the potential risks and complications as discussed with him.

During the attempted extraction, the 26 did fracture and the disto-buccal root remained in situ. A second radiograph confirmed the position and size of the retained root fragment. The dentist did attempt to remove the retained root but was cautious given the high risk of displacing the root into the antrum. Mr G was informed that the extraction was incomplete and that, as a piece of the root was retained, it would now be necessary to refer him to a specialist colleague.

The dentist provided the necessary aftercare and arranged for a review appointment. During this appointment, Mr G mentioned that he was unhappy about the additional costs that would be incurred in order to complete treatment with the oral surgeon, and asked the dentist to reimburse these additional fees.

The dentist contacted Dental Protection and discussed the case with a dentolegal consultant, who acknowledged the dentist had made comprehensive notes and documented all her discussions with Mr G, including the specific risk of fracture of the disto-buccal root. The records also noted that the patient had declined the option of a referral to a specialist colleague before any treatment had started.

Dental Protection advised the dentist that her treatment records clearly reflected that valid consent had been obtained, and whilst the outcome was suboptimal, the dentist had provided appropriate treatment with a reasonable degree of skill, and had discontinued the treatment when she felt the removal of the retained root required specialist intervention.

It was agreed that there were strong grounds for the dentist to decline Mr G's request to reimburse the additional treatment costs, and Dental Protection assisted the dentist in providing an explanation of events in a letter to Mr G. In addition, it was suggested that the dentist may wish to consider refunding the fees for the incomplete extraction, purely as a gesture of goodwill to maintain an amicable dentist-patient relationship.

Mr G acknowledged that he was informed of this possible outcome and had agreed that the immediate referral and standard of aftercare had been to his total satisfaction. He accepted the refund of the treatment fee for the attempted extraction and indicated his appreciation of the gesture of goodwill.

Mr G remained on good terms with the dentist throughout, and later informed her that the retained root had been removed uneventfully by an oral surgeon.

LEARNING POINTS

- By providing the patient with all the treatment options and identifying the advantages and disadvantages of each, along with the associated costs – such as the offer of specialist referral – a dentist can be confident that the choice made by the patient is take back.
- Ensuring all discussions with the patient are recorded contemporaneously allows a dentist to rely on their treatment records to defend their position.
- A dentist should always ensure they are working within their clinical competency and be able to recognise when treatment may have progressed beyond their particular expertise or skill set, and provide prompt referral to a specialist colleague when necessary.
- Whilst in this instance the patient accepted the dentist's explanation and appreciated the goodwill gesture, if the patient had chosen to escalate their concerns by pursuing a claim for compensation, Dental Protection would have been in a good position to defend against any attempted litigation because of the dentist's robust treatment records.

Case Study

A delayed postoperative healing following an extraction



Mrs C attended her dentist for an extraction of an unrestorable, fractured 37. The procedure was uneventful and postoperative instructions were provided in the usual way.

She returned a few days later in discomfort and the dentist diagnosed alveolar osteitis. The socket was irrigated and the dentist placed a medicated dressing in the socket. The dentist explained the diagnosis, advised Mrs C to take painkillers and offered to book a review appointment the next day.

Mrs C seemed surprised about this and declined the appointment as she had already taken two days off work to attend the clinic for the extraction and the emergency appointment. As there were no signs of infection, antibiotics were not prescribed and she left fairly disgruntled.

Her husband returned to the clinic the next day shouting and being very raucous in his behaviour. He complained to the receptionist that his wife was still in considerable pain following the extraction of her tooth, and stated that this was down to the poor standard of treatment provided by the dentist. He threatened to report the dentist to the press and contact a lawyer and said that he had already posted negative comments about the dentist on various social media sites.

The dentist in question was working in another clinic that day, so did not have an opportunity to provide an explanation to Mrs C's husband. He did however contact Dental Protection for urgent advice as he was concerned about the impact of any social media criticism. He discussed the case with his dentolegal consultant and explained that although he was unaware of any press coverage to date, there were a handful of comments on social media attempting to undermine his credibility and professional reputation.

The press team at Dental Protection was asked to assist the member and advised that if the dentist was contacted by a newspaper for a comment, he should find out:

- the journalist's name
- the name of the publication
- the aspects of the care and treatment they were seeking comments on
- the deadline for a response
- the journalist's contact details – phone number and email address.

The press team also provided the following helpful advice:

- Do not respond to any questions immediately – instead take some time to consider a response or to seek advice.
- Maintain your professionalism at all times and do not be tempted to discuss a patient's treatment in a public domain. If you cannot discuss the patient's treatment for confidentiality reasons then you should say so.
- Avoid saying 'no comment' as it sounds defensive. Ensure you come across as co-operative and inform the reporter that you will come back to them.
- Contact the Dental Protection press office for advice and liaise with your employer/practice where appropriate.

The dentist was reassured that the press team could liaise with journalists if necessary and provide a statement on his behalf.

Steps were also taken to address the negative comments made on social media; the administrator of the social media page was contacted and the unfair and inappropriate comments were asked to be removed.

Dental Protection recognises that patients increasingly use social media channels to highlight concerns about their treatment and care where previously this would have been privately communicated to the practice. We would encourage members to respond to both positive and negative online feedback. Responding to online comments demonstrates you are listening and care about feedback; however, you should always express a willingness to address any concerns offline where confidentiality can be respected.

The situation was amicably resolved by arranging for another dentist to review Mrs C. This dentist confirmed the diagnosis and explained to the patient that dry socket was a recognised complication and that the pain would subside within a few days and the socket would heal.

It is always advisable to request Dental Protection's assistance from the outset when faced with unexpected clinical outcomes and/or complications that may lead to a patient complaint. In this situation, the dentist was able to identify a strategy to manage the adverse social media coverage and potential harm to his reputation by contacting Dental Protection immediately.

LEARNING POINTS

- **The dentist failed to warn the patient about the possibility of alveolar osteitis at the outset. Consequently, when the patient developed a recognised post-operative complication she became alarmed and blamed the dentist.**
- **An opportunity was also missed when the dentist realised that the patient left the clinic unhappy. It may have been worthwhile considering contacting the patient later on that evening to enquire how she was and provide further support and advice.**

Case Study

Leaving a sour taste in the mouth



@kulpicoo@gettyimages.co.uk

Associate dentists leave their current practice for a variety of reasons, and occasionally this can be due to a breakdown in communication and issues surrounding working relationships within the practice. When an associate leaves a practice on bad terms this can be the catalyst for a number of unexpected patient complaints. This scenario can be distressing and difficult to manage if there is no agreement with the practice principal in relation to how to manage post-treatment issues that would otherwise be addressed by the dentist had they remained at the practice.

It is common practice for an agreed sum of money to be withheld by the principal for an agreed period of time when an associate leaves a practice, to allow minor problems to be resolved.

CASE STUDY

The relationship between a principal and an associate had deteriorated to such an extent that the associate left the practice.

The associate was clinically very competent and experienced, and had completed a number of challenging 'tooth wear' cases. One particular patient, Mr L, had been treated with composite build up restorations on numerous teeth to conservatively treat his tooth wear and the finished result was satisfactory. Whilst the associate's clinical records reflected the merits and limitations of composite resin versus porcelain restorations, there was no mention that further charges would apply for the maintenance and/or repair of these restorations. When Mr L required some fairly minimal general polishing of the composite restorations due to surface staining, he said he had not been informed that additional charges would apply and did not expect the owner of the practice to charge him for this treatment.

Mr L resented being asked to pay for polishing the composites and raised the issue with the principal, who passed the complaint to his former associate. Although the associate had moved over 70 miles away, he offered to review the patient and provide the necessary treatment at no cost, but the patient was understandably unwilling to travel to take back.

This scenario was not an isolated example; it was a recurring story involving a number of patients who required similar maintenance work. Rather than completing this work as a gesture of goodwill to maintain the reputation of the practice, the principal encouraged every minor concern to develop into a complaint that required a formal response from the associate. The fact that the patients were being charged an over-inflated cost for treatment by the principal only added to their dissatisfaction.

The associate contacted Dental Protection, and with the benefit of hindsight, realised that he had not made it clear to Mr L – or to the other patients – that ongoing treatment would be chargeable. He recognised that there had been no clarity regarding what aspects of the treatment were covered by the original fee, and as a result, patients had unilaterally made some assumptions.

Dental Protection advised the associate to talk to the principal and to try and come to an agreement so as to avoid further incidents that could be harmful to both their reputations.


The associate and principal reached an agreement between them to cover the reasonable cost of post-treatment maintenance/polish appointments.

LEARNING POINTS

- This case study illustrates the importance of maintaining professional relationships and taking the time to agree how patient care can, and should, be handed over when a dentist leaves a practice.
- There should be a signed agreement that includes a clause regarding the retention of fees for remedial work when an associate leaves a practice. This avoids disputes and disagreements that may arise after the departure of an associate.
- When planning treatment that requires ongoing maintenance, clear explanations should be given to the patient and documented in the record. This should include an explicit statement as to what the initial fee includes and what charges may apply in the future. This should be set out clearly in writing for the patient and a copy retained in the records, so everyone knows what to expect.
- Financial disputes between the principal and an associate should be resolved between the two parties and not involve the patient.

Case Study

Protecting your reputation



A dentist provided functional orthodontic treatment for a ten-year-old patient.

The treatment did not get off to a good start due to the patient failing to fully comply with advice and instructions on the requirement to wear the appliance.

The mother wished to discontinue treatment so she could seek care elsewhere for her child, in the hope they would have better success. The dentist thought he had resolved the situation amicably by providing a copy of the records to facilitate ongoing care and a full refund of fees.



As well as the defamatory comments published on Google, the patient's mother also sent a number of threatening emails to the dentist

The patient attended another practitioner and it became apparent that the patient's mother had posted a Google review about the first dentist, alleging he was a terrible dentist; that he caused harm to her and her son; and that his motivation was financial.

As well as the defamatory comments published on Google, the patient's mother also sent a number of threatening emails to the dentist.

The dentist worked in a small, close-knit community, and news of these harmful, negative reviews spread quickly and started to have a negative effect on the popularity of the practice.

Shortly after the dentist contacted Dental Protection, a barrister was instructed to assist. The barrister prepared a strongly worded letter to the mother to 'cease and desist' her actions, consequent to which the reviews were removed and the persistent, threatening emails ceased.

LEARNING POINTS

- Dental Protection is here to support you, and because we have the legal resources on hand to support members when it matters most, we can act quickly to advise and protect your professional reputation.
- Practices should remain vigilant and monitor any comments on websites and social media platforms and seek advice if they have the potential to damage the professional reputation of the practice.
- If you receive a request for clinical records, be aware of any latent and underlying concerns and try and resolve these within the practice. This is an example of risk containment.
- Whilst a refund of fees can de-risk the escalation of a complaint, be aware that patients can seek redress in other ways, including commenting on their experience on websites.
- It is important that patients are fully informed of charges and fees, but be aware that information about costs should be presented in a way that does not suggest to the patient that it has primacy over other discussions. This may lead to the perception that a dentist is interested only in the fee.

Case Study

Short term orthodontics



©TAndreyPopov@gettyimages.co.uk

Miss N attended an examination appointment with a new dentist, unhappy with the appearance of her upper teeth. She informed the dentist that she'd had an assessment with an orthodontist a few years ago and was told fixed appliances were necessary. Miss N wanted a 'quick result' as she was getting married in six months and was aware the dentist provided a clear aligner treatment system. The dentist carried out some checks using the clear aligner system programme and informed her about the costs of the treatment, indicating a good result was possible within six months. Miss N was happy to proceed on this basis.

Treatment continued for four months, with Miss N becoming increasingly frustrated at each review by the lack of progress. The dentist queried whether she was wearing the aligners for the prescribed periods of time. Miss N reassured the dentist she was indeed wearing the aligners for the correct periods of time and was anxious to have the treatment finished due to her wedding drawing near. The dentist continued to reassure her and consulted with the clear aligner programme mentor who advised that additional aligners were now necessary.

The dentist relayed this to Miss N at the following review. Although she was extremely disappointed, she still wanted to continue treatment and accepted this would not be finished by the time of her wedding.

A further five months passed and it became apparent that the case was not progressing how Miss N had expected. She also began to experience occlusal problems and had developed an anterior open bite. The dentist

accepted that progress had been slow and offered to refer her to an orthodontist.

The orthodontist advised that due to Miss N's crowding and the skeletal profile, tooth extraction and fixed appliances were necessary in order to correct the treatment. The patient was extremely upset and complained in writing. She alleged that the dentist had misled and misinformed her at the time of the initial examination about the duration of the treatment to achieve the desired result. She requested the dentist refund the treatment fees and cover further costs to continue her care with the specialist orthodontist. Miss N threatened to seek compensation for negligence if she did not receive what she believed to be a fair and satisfactory outcome.

The dentist contacted Dental Protection for advice. A close scrutiny of the patient's clinical records indicated that these were insufficient and incomplete and therefore it could not be shown that an appropriate examination and subsequent diagnosis had been made, or that a suitable treatment plan had been formulated. As a result, the dentist would be vulnerable in the event of an escalation and further inquiry. The records suggested that treatment options – such as fixed appliances and/or referral to a specialist orthodontist – had not been discussed, which amounted to a failure in obtaining valid consent. A specialist orthodontic report concluded that due to Miss N's severe crowding, she would always have needed fixed orthodontic treatment to achieve a satisfactory outcome.

Although the treatment was initially an elective procedure, Miss N's occlusion was now unstable and further treatment was necessary. Dental Protection discussed with the member whether he would be prepared to refund the treatment costs in view of the patient's dissatisfaction, and he agreed.

With Dental Protection's advice and assistance a letter was sent to Miss N. It included an apology and the case was resolved by a refund of treatment fees and a contribution towards the additional cost of further treatment with the specialist orthodontic consultant.

LEARNING POINTS

- Ensure all treatment options – and any appropriate referrals – are offered to the patient, along with the advantages and disadvantages of each, in order to demonstrate a valid consent has been achieved.
- Be aware of your professional limitations and work within the limits of your competence.
- Assess each case carefully to avoid attempting treatment beyond your clinical capabilities, even if the patient demands it.
- Do not agree to unrealistic or impracticable treatment times.

CONTACTS

You can contact Dental Protection
for assistance dentalprotection.org

Membership services

Telephone +44 113 241 0727

caribbeanandbermuda@medicalprotection.org

Dentolegal advice

Telephone +44 207 399 1400

enquiries@dentalprotection.org

Dental Protection Limited is registered in England (No. 2374160) and is a wholly owned subsidiary of The Medical Protection Society Limited (MPS) which is registered in England (No. 36142). Both companies use 'Dental Protection' as a trading name and have their registered office at Level 19, The Shard, 32 London Bridge Street, London, SE1 9SG.

Dental Protection Limited serves and supports the dental members of MPS with access to the full range of benefits of membership, which are all discretionary, and set out in MPS's Memorandum and Articles of Association. MPS is not an insurance company. Dental Protection® is a registered trademark of MPS.