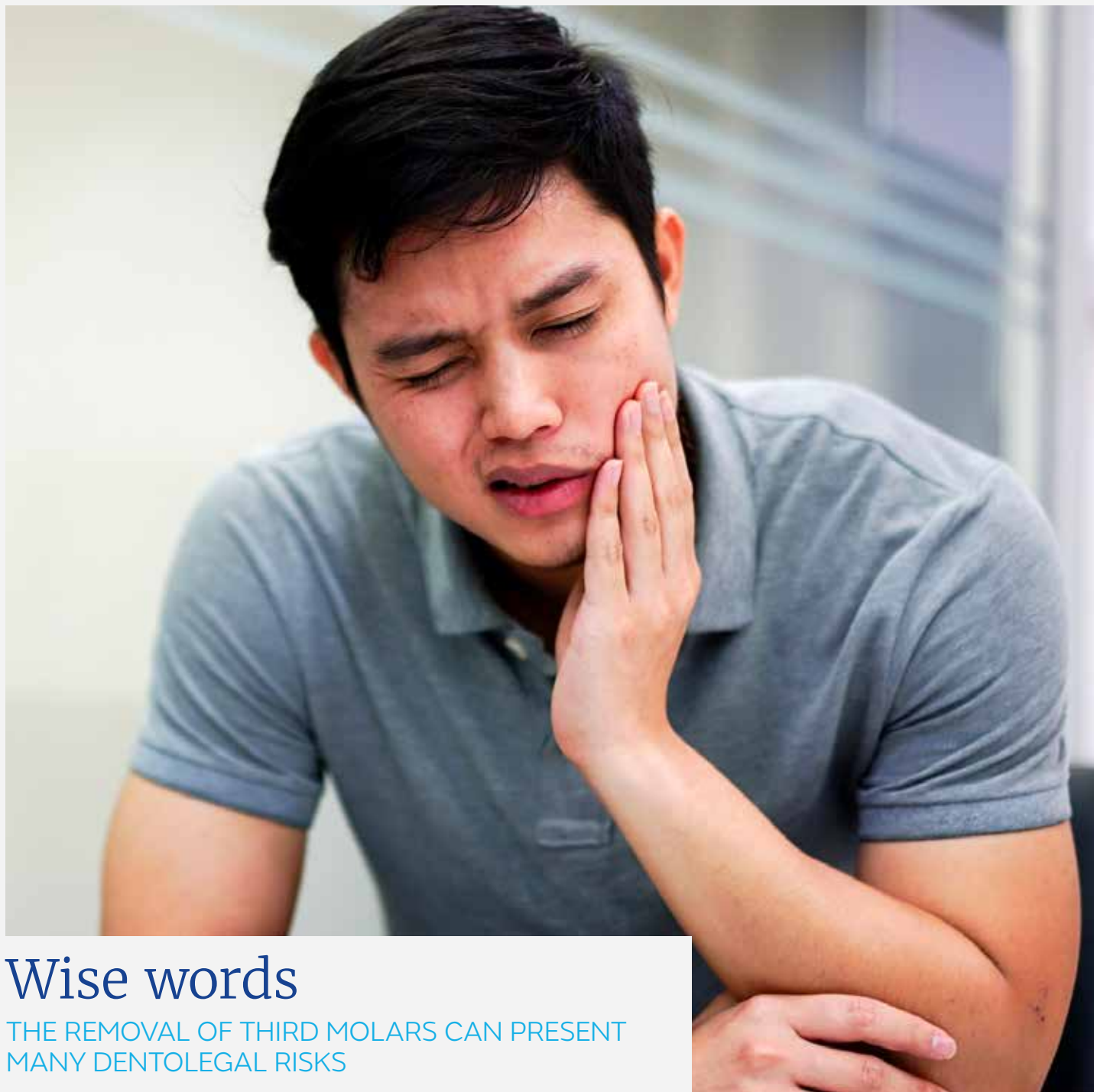



RISKWISE

ISSUE 17 | JANUARY 2019

SINGAPORE



Wise words

THE REMOVAL OF THIRD MOLARS CAN PRESENT MANY DENTOLEGAL RISKS

THE BUSINESS OF DENTISTRY
Managing the relationship with patients

SUPERVISING OTHERS
What risks are you exposed to when supervising others?

SAYING 'SORRY'
When and why should you apologise



HIGHLY SPECIALIST ADVICE FROM A FELLOW DENTIST

- ✓ Talk dentist-to-dentist
- ✓ Support on a wide range of dentolegal issues
- ✓ Impartial, confidential and dentolegal support

Dental Protection has provided a **highly specialist** service to dentists for 125 years.

Our team of fellow dentists offer a personalised and impartial service to protect your career and reputation.

Find out more at dentalprotection.org

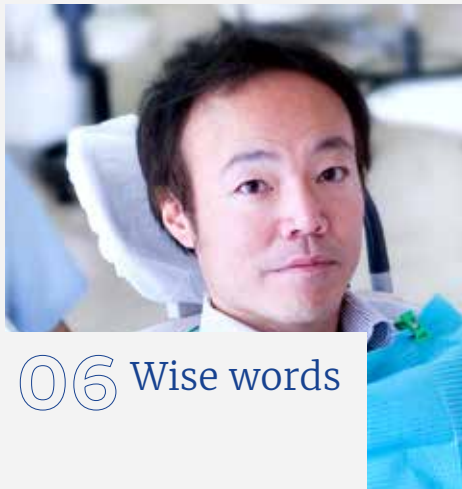Speak to us about MEMBERSHIP **+03 78876760**

Contents



05 New dental records workshop proves popular

The workshop provides information on the importance of keeping dental records.



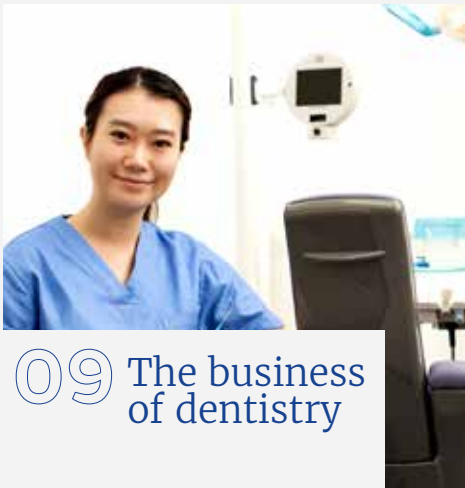06 Wise words

The removal of third molars can present many dentolegal risks.



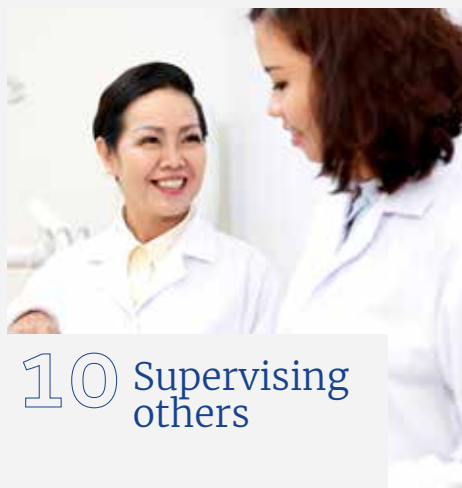08 Saying 'sorry' could make all the difference

When should you apologise and why is it so important?



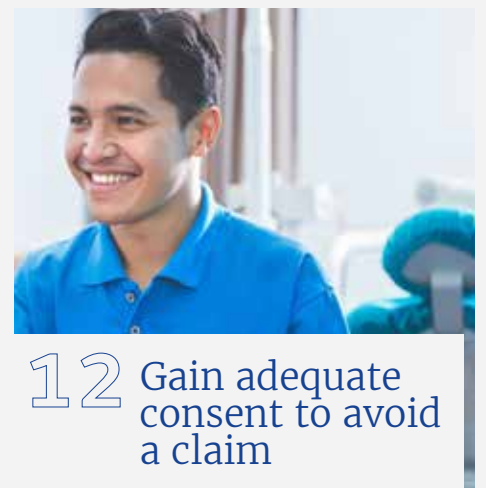
09 The business of dentistry

Dr Raj Rattan explains the importance of managing the relationship with patients when working in general dental practice.



10 Supervising others

What risks are you exposed to when you are supervising a colleague?



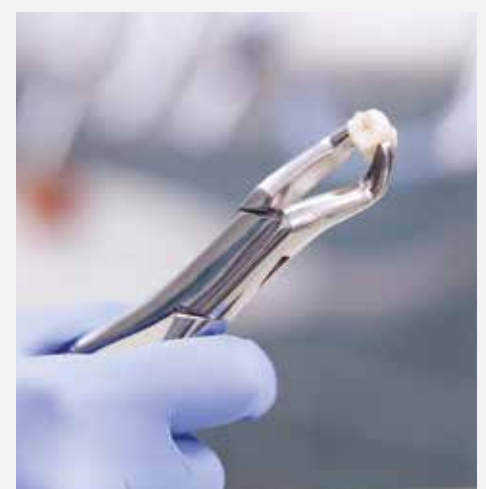12 Gain adequate consent to avoid a claim

How to effectively manage your patient's expectations and record adequate consent to mitigate the chance of a claim.



13 - 18 Case studies

From the case files: practical advice and guidance from real life scenarios.



Editor
Anna Francis

Production
Emma Senior

Design
Conor Walsh

Print
Sampoorna Printers

Editorial

DR JAMES FOSTER

Head of Dental Services Australasia/Asia



WELCOME TO THIS LATEST EDITION OF **RISKWISE, DENTAL PROTECTION'S FLAGSHIP PUBLICATION OFFERING THE LATEST INFORMATION ON DENTOLEGAL TOPICS AND ADVICE FROM OUR DENTOLEGAL CONSULTANTS AND PROFESSIONAL EXPERTS.**

In this edition, our dental director, Dr Raj Rattan, explains the importance of building trust with our patients, which in turn enables longer relationships, reduces the incidence of conflict and complaints, promotes satisfaction and can build loyalty.

Making an appropriate apology when things go wrong is not an admission of liability. In fact, it can be a powerful expression of empathy and acknowledgement, which in turn helps defuse a complaint and prevent it from escalating.

There are some common issues arising from wisdom tooth surgery where unfortunately a growing number of cases have been noted. Assessment, technique and of course consent are the common areas placed under scrutiny when a claim or investigation arises.

Dental Protection's general manager for Asia Pacific Educational Services, Matthew O'Brien, describes the new workshop – 'Dental Records for Dental Practitioners' – which highlights the importance of well-organised dental records to aid continuity of care and ensure good practice. Through a range of presentations, discussions, case scenarios and practical exercises, it highlights the importance of accurate and up-to-date dental records for both patient care and professional defence.

FURTHER CPD

Prevention is better than the cure, and Dental Protection provides expert advice, support and education to help you understand and manage your risks. I was fortunate to have the opportunity to share insights with members at Singapore IDEAS in August and it is hoped Dental Protection will provide more events going forward, including further presentations, webinars and webcasts. Please visit our website for updates on these events – as well as others – and for information on our other substantial e-learning opportunities.

A WORD ON THE TRUE PRICE OF PROTECTION

Dental Protection is proud to have supported thousands of healthcare professionals since its inception. Whilst many other organisations have come and gone, we are committed to supporting professionals in Singapore for many years to come.

Dental Protection understands members want more certainty in how their risk is determined and how much they will pay for membership at their next renewal. Our approach is to stabilise membership subscriptions as much as possible, setting prices according to the long-term trends in cases and claims experience, and smoothing over any sudden fluctuations.

With decades of experience in dealing with complex clinical negligence cases in Singapore, Dental Protection is able to use this experience to more accurately price the risks and defend dental members when in need.

Subscriptions are set aside to meet the future likely cost of the risk that members face. When setting subscriptions, Dental Protection undertakes a detailed and robust actuarial assessment of the cost of supporting members in each country. This includes analysing the number of claims and cases experienced by members for each specific area of practice, along with the cost of assisting with those claims and the likelihood of claims arising in the future for each specific area of practice. Additionally, Dental Protection will look at how much it costs to provide member benefits and any non-claims costs, such as assisting with cases before the Singapore Dental Council, and estimate how much those costs could go up in future years.

This is built into subscriptions so that we have enough funds set aside as reserves for future assistance. This means that Dental Protection can be confident of supporting you and offering the best support and advice available throughout your career and beyond.

Thank you for taking the time to read *Riskwise* and I hope it has been useful. It is always helpful to hear feedback from members, so if there are other topics you would like us to cover or changes you would like us to make, please let us know.

Best wishes,

Dr James Foster LLM BDS MFGDP (UK)

Head of Dental Services Australasia/Asia

james.foster@dentalprotection.org

JAMES FOSTER

James qualified from Newcastle Dental School in 1990 and was in General Practice for sixteen years during which time he ran two practices in Northumberland.

James had various roles with the Northern Deanery, which included seven years as a vocational training adviser (latterly as a General Professional Training scheme adviser), workforce adviser, dental tutor and a Professionals Complementary to Dentistry

tutor. He also worked as a clinical supervisor in prosthodontics at Newcastle Dental Hospital for four years.

James obtained a master's degree in Medical Law in 2005, and has further obtained the MFGDP (UK) and a certificate in Clinical Education. James is also a trained mentor and following his appointment as a local adviser to Dental Protection in 2004, he was

further appointed as an associate dentolegal adviser, before becoming a full-time dentolegal adviser in March 2008.

James handles cases from several international jurisdictions, and in 2014 he was appointed Head of Dental Services for Australia and New Zealand, and has now taken over the same role for Asia.



New dental records workshop proves popular

Over 580 members across the Asia Pacific region attended Dental Protection's new 'Dental Records for General Dental Practitioners' workshop, which launched earlier this year.

The dental records workshop provides information on the importance of keeping dental records (paper and electronic) to enable the dental team to provide the best possible patient care and dentolegal protection.

Almost all participants agreed that they would change the way they practise as a result of what they had learnt, with the majority of participants strongly agreeing that the workshop was relevant to them, and rating it an average 6.81 score on a 7 point scale.¹

Dental Protection's general manager for Asia Pacific Educational Services, Matthew O'Brien, said: "Complete, contemporaneous and well-organised records are essential for

good dental practice and continuity of care. They are necessary for your defence against a claim or complaint and can be seen to reflect the quality of care provided.

"The workshop helps members reduce their risk of patient complaint by covering the legal, regulatory and contractual requirements of record keeping in general practice."

Feedback from members who had attended was overwhelmingly positive. One stated: "Examples of well-written records were very useful. I was unaware until now that this is the standard we are expected to abide by." Another member said: "The workshop was very good and relevant to all forms of practice."

Members who attended the workshop also received a best practice clinical entries checklist. The checklist is a useful tool to ensure records contain sufficient enough information for a seamless handover of care if required.

The new dental records workshop is one of several in Dental Protection's Risk Management series. Mr O'Brien said the workshops were highly valued by members, who find the case studies, clinical examples and personal experiences relevant to their day-to-day practice.

"It was great to have case studies and personal experiences from both the presenter and each other to learn from," said one attendee.

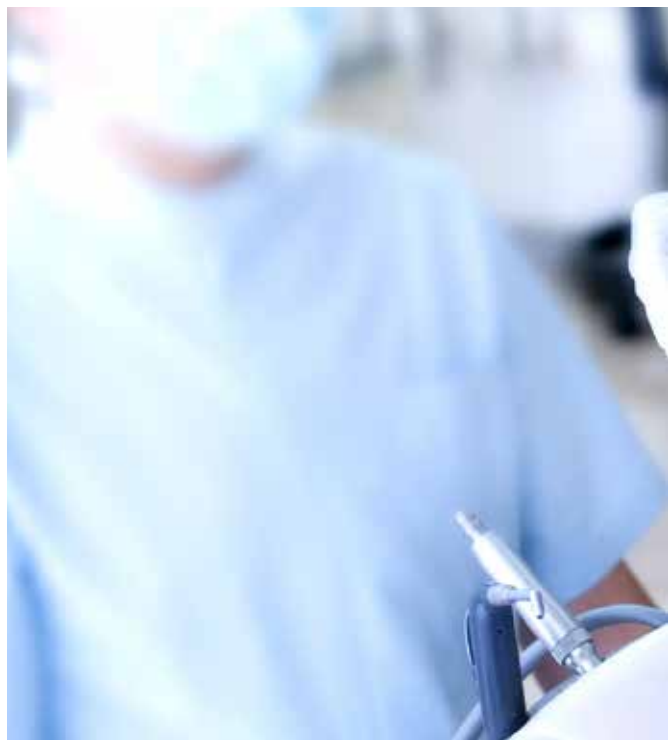The workshops were very popular, with most workshops oversubscribed across the region. Based on demand, the dental records workshops will continue to run into 2019.

To learn more about attending a workshop in your area, visit dentalprotection.org

1. Dental Records for General Dental Practitioners Evaluation Summary statistics for Asia Pacific

Wise words

Patients usually attend for removal of their 'wisdom teeth' fearing the worst



While developments in dental technology, equipment and materials have transformed many dental procedures over the years, the removal of third molars still presents many of the same dentolegal risks as in former years. Perhaps the most significant factor, of which we need to be aware, is that while the procedure itself might be broadly the same, many of the patients involved are not.

The fact that today's patients have greater expectations, and are often more aware and more questioning is only half the story; it is equally important to appreciate that today's patients are generally less forgiving, less tolerant of adverse outcomes, and more litigious.

PREOPERATIVE ASSESSMENT

- Correct diagnosis – if you are considering the extraction of a third molar because of non-specific pain, how sure are you that the third molar is actually the cause of the pain, rather than being seized upon as a convenient scapegoat to explain it, where other investigations have failed to do so?
- Appropriate investigations – including one or more good quality radiograph which not only provides a clear image of the tooth, its root configuration and anatomy, and the surrounding bone, but also the relationship of the tooth to adjacent teeth and to other structures. Significant amongst these are its relationship to the maxillary tuberosity and sinus, to the lower border of the mandible, to the ascending ramus and to the inferior dental (alveolar) nerve bundle within the mandible.
- Check the medical history carefully, and in particular, any relevant risk factors (including medication) that might influence:

- a) bone and soft tissue healing
- b) the likelihood of postoperative bleeding, swelling and infection.

Of increasing concern is the potential for postoperative complications related to patients on bisphosphonate medication, which can affect wound healing and increases the risk of medication-related osteonecrosis of the jaw (MRONJ).

- The social history is particularly relevant when contemplating this procedure and it is sensible to enquire specifically as to the patient's occupation and any important life events. Nerve damage and the associated sensory deficit can have devastating consequences for patients in certain industries where use of the mouth and palate is essential. Pericoronitis is not uncommonly associated with stress and other factors influencing the host response, and with appropriate management, the symptoms will often resolve without needing to extract the tooth at all.

Taking all the above into account, the consequences of any adverse complication need to be carefully balanced against the indications for the extraction(s), in the specific circumstances of each individual patient.

- Are the risks of leaving the tooth in situ greater than the risks of extraction?
- How many episodes of pericoronitis have there been, of what severity, how were they managed and with what success?
- Is there caries in the third molar or in the adjacent tooth?

- Is there any clinical or radiographic evidence of pathology associated with the third molar?

One final consideration in the preoperative assessment is whether the clinician has the necessary skills, experience and competence to carry out the proposed extraction safely and successfully. Where there is any doubt in this respect, a referral to a specialist may be indicated.

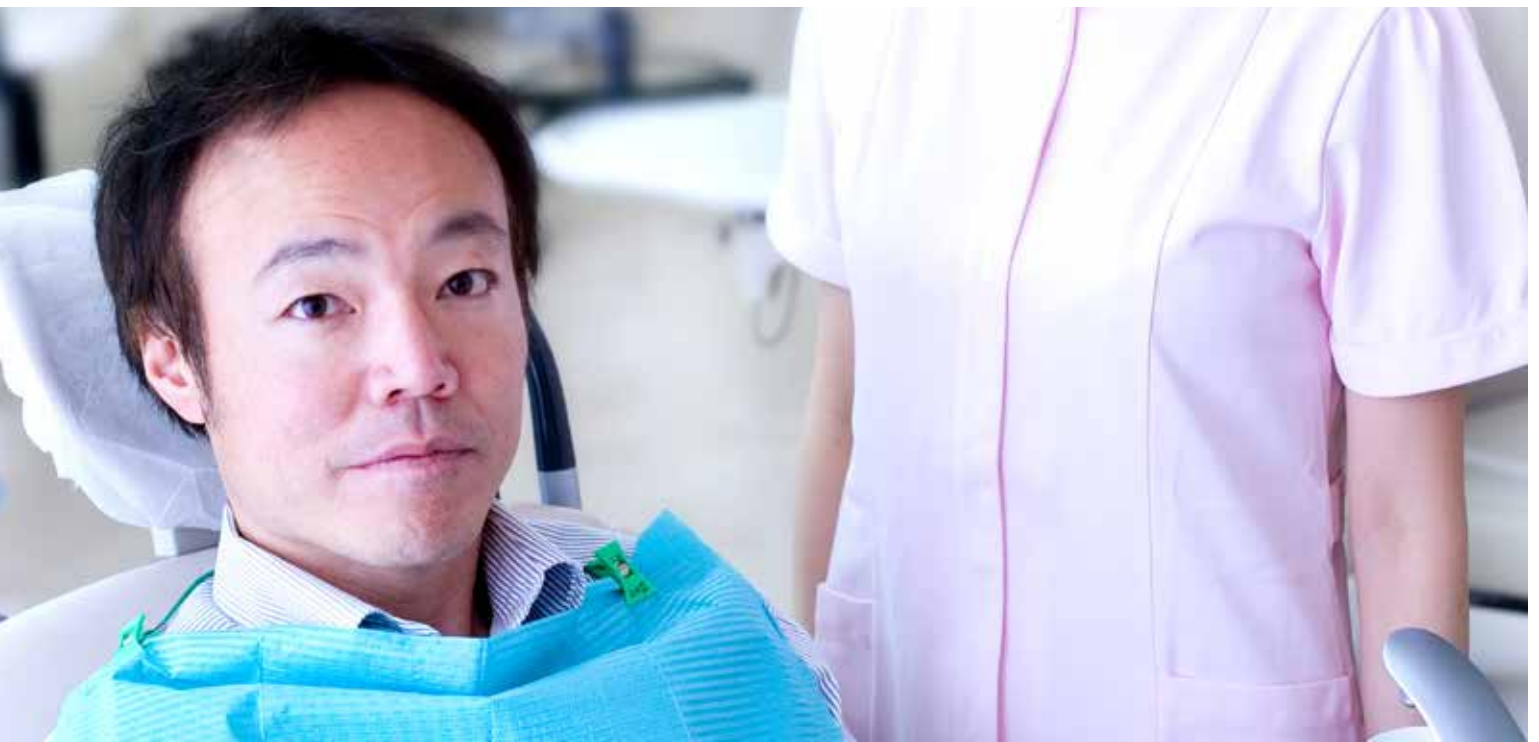INFORMATION, WARNINGS AND CONSENT

Any surgical procedure has risks. It is important to take the time to explain carefully to the patient, in terms that the patient can understand:

- a) why the extraction is considered to be necessary
- b) what the procedure involves
- c) what the possible outcomes might be.

It is equally important to record in the notes the fact that this has been done. Patients will generally not be able to anticipate these complications for themselves, and the clinician has a duty of care to give the patient any explanations and warnings necessary to enable the patient to consent to the procedure with a full knowledge and understanding of what to expect.

Although information leaflets and advice sheets can be very helpful in assisting the patient to understand what the procedure involves, one must bear in mind that each procedure, and each patient, is different. Patients need to know what the risks are in their individual case, rather than being given information of a general nature, perhaps



accompanied by statistical assessments of the incidence of complications reported in the professional literature.

Those who accept referrals from colleagues for the removal of third molars need to be aware that one of the treatment alternatives is still to leave the tooth (or teeth) in situ.

There is a danger that both the referring clinician, and the clinician who accepts the referral, will each be assuming that the other is responsible for the consent process, including discussing with the patient whether or not it is sensible to be considering the extraction(s) at all.

SURGICAL TECHNIQUE

There is a commonly held misconception that the raising of a buccal flap only, and avoiding bone removal on the lingual or disto-lingual aspect of the tooth, will avoid any risk of lingual nerve damage. It is true that in the literature, the raising of lingual flaps, the use of lingual retractors and/or the use of relieving decisions in the retromolar area, have all been associated with a higher risk of lingual nerve damage. It is equally true, however, that many experienced oral and maxillofacial surgeons use these techniques routinely and yet experience a very low incidence of lingual nerve damage.

In the case of inferior dental nerve damage, where there is close proximity between nerve bundle and root apex, the surgical technique (for example, sectioning the tooth) must be such as to minimise the risk of severing, stretching, tearing or compressing the nerve bundle.

COLLATERAL DAMAGE

In addition to nerve damage, one needs to be mindful of the risks of fracturing the mandible (or leaving the mandible weakened and vulnerable to spontaneous fracture postoperatively), fracturing the maxillary tuberosity, or damaging adjacent teeth. This can range from dislodging fillings and crowns, to iatrogenic damage from burs and other instruments, to the distal surface of the second molars.

In each of these situations, by remaining alert to the potential risks and taking some simple steps to minimise them, the clinician can help many of the associated problems.

POSTOPERATIVE MANAGEMENT

Patients who are not adequately prepared for some of the adverse complications of third molar surgery, can find them very distressing.

The extent of any swelling, pain, bruising and discomfort can vary widely from one patient to another, but altered sensation can be very worrying for patients unless they have been made aware that temporary sensory disturbance of this kind is not unusual, and does not necessarily indicate that anything has gone wrong with the procedure.

Caring and attentive aftercare is the key to preventing this commonly encountered complication from becoming the basis for a complaint or claim.

Where postoperative complications do occur, the records should show clearly what the patient was complaining of, what steps were taken to investigate the problem, the differential diagnosis and the treatment provided or advice given (including any medication given, prescribed or recommended). If a referral for specialist advice/management is considered or

discussed, a note of this should appear in the records.

Record negative findings (e.g. 'no lymph node enlargement or tenderness' or 'checked for mandibular fracture/lower border intact') as well as positive findings (e.g. 'swelling reduced'). The importance of this lies in being able to demonstrate that all the appropriate investigations were carried out, before reaching the diagnosis and treatment plan.

Postoperative instructions should be given, perhaps with the help of a printed advice sheet, and this fact should appear in the clinical records. If the patient chooses not to follow the advice given, this should also be clearly recorded.

Arrangements to review the patient's progress should be clear, mutually agreed and recorded in the notes.

RECORDS

Each one of the steps described above needs to be meticulously recorded in the clinical notes. In our experience, deficiencies in such records are much more likely to render a claim or complaint indefensible, than any shortfalls in the clinical technique itself.

Accurate, contemporaneous clinical notes are critical when dealing with allegations of inadequate postoperative assessment, or a failure to warn appropriately of risks, or problems arising from a poor technique, or shortfalls in postoperative management.

Saying 'sorry' could make all the difference

An apology can often go a long way in resolving a complaint or avoiding one in the first place



Unfortunately things do go wrong in dental care and sometimes patients are dissatisfied, disappointed or upset with the care that they have received. Dental Protection advises members that an apology is not an admission of liability; rather, it is an acknowledgement that something has gone wrong and a way of expressing empathy.

APOLOGISING CAN AVOID AND RESOLVE COMPLAINTS

Contrary to popular belief, apologies tend to prevent formal complaints rather than actually cause them. An apology and an explanation can provide reassurance to a patient and is often all the patient is looking for. When patients are aggrieved, or feel that they have been harmed by treatment, it is important for the professional person to acknowledge those feelings and to express regret for what has happened – irrespective of where any fault might lie. The lack of an apology in these situations is one of the reasons why patients take complaints further.

Concerns about the consequences of speaking up mean that members of the dental team sometimes hesitate to act when things go wrong. The desire to seem infallible, coupled with a fear of recrimination, can stifle an open approach to errors. As a result, a natural apology and explanation to patients can be lost. However, an apology can reassure your patient that you understand their situation.

WHEN SHOULD AN APOLOGY TYPICALLY BE OFFERED?

An apology should be offered as soon as it becomes apparent that an adverse incident has occurred (regardless of fault) or if the patient is unhappy with their care or some aspect of their account. It is important that patients receive a meaningful and timely apology. It may be some time before all the facts are understood, including perhaps the reasons why and how the events occurred. However, this consideration should not delay a prompt apology.

The culture within a clinical setting should allow dentists the freedom to apologise. It is ethically and professionally the right thing to do – irrespective of the cause.

WHAT IS AN 'APPROPRIATE' APOLOGY?

An apology is appropriate when a patient has suffered harm from their dental care or experienced disappointment. It should be tailored to the situation to reflect the patient's perception of the issue.

For example, 'I am sorry this happened to you' is an expression of empathy, rather than, 'I am sorry I caused this to happen to you and it's my fault...'

Providing context can ensure all parties understand the purpose of the apology. Ownership should also be taken by a senior clinician. Fundamentally, an apology should be offered willingly, and not perceived to have been given reluctantly.

WIDER BENEFITS

Dental Protection would always advocate a full and objective review of an adverse event, with the patient being informed about any resulting learning points. A commitment should be made to understand and learn from what has happened in a blame-free manner, to reduce the likelihood of it reoccurring and happening to someone else. Most importantly the patient will understand what happened, receive an apology and get recognition of the distress they feel.

The Dental Protection workshop 'Mastering Adverse Outcomes' gives you the tools to successfully communicate with your patients should they experience an adverse outcome during their care. Find out more at dentalprotection.org.



The business of dentistry

Dr Raj Rattan, dental director at Dental Protection, explains the importance of managing the relationship with patients when working in a general dental practice

At the heart of every valued human interaction lies the notion of trust. Our world could not function without it.

Trust is one of the most important constructs in the dentist-patient relationship. It creates longer and more stable professional relationships, reduces the incidence of conflict, promotes satisfaction, reduces complaints, and builds loyalty. It is, therefore, one of the key drivers of success in general dental practice.

WHAT IS TRUST?

There are many definitions of trust that identify credibility, benevolence, confidence in honesty, and reliability as key components that can lead to trust being established. We make promises to our patients and our patients expect us to keep them. They expect us to be knowledgeable, skilful and competent. As Joseph Graskempner noted in his article in JADA: “dentists should gain the patients’ trust in them as reasonably knowledgeable, reasonably talented, caring dental health providers”.¹

CAN TRUST BE QUANTIFIED?

$$\text{Degree of trust created} = (R \times C \times I) / SO$$

R= reliability, C= credibility and I= intimacy are multipliers and self-orientation (SO) is the divisor.

Significantly, the greater the divisor, the lower the quantity of trust generated.

CREDENCE MARKETS

In economic terms, dental services fall into the category of credence goods. Patients don’t always know whether they need the suggested treatment, and in some cases even

after they receive the treatment, they cannot be sure of its value. This is because the ‘buyer’ does not have the knowledge of the ‘seller’ – a feature of the dentist-patient relationship referred to as ‘information asymmetry’. It is this asymmetry that makes the credence goods market particularly challenging because it may give rise to aberrant behaviours.

It is interesting to note the comments made in 2012 by Brown and Minor in their paper ‘Misconduct in Credence Good Markets’.² “Providers of technical advice are common in the automotive, medical, engineering, and financial services industries. Experts benefit from customers trusting and buying their advice; however, experts may also face incentives that lead them to provide less than perfect recommendations. For example, a mechanic can provide a more extensive fix than warranted and a dentist can replace a filling that has not failed.”

The need for regulation to protect the consumer in the credence space is implicit. Another challenge is that perceptions of clinical success and failure in this market are largely subjective for patients, because there is no external verification. It is only because of trust that patients do not routinely seek to independently verify every transaction and clinical outcome.

KEY COMPONENTS OF BUILDING TRUST

Building trust should underpin a practice’s risk management strategy. Without this, any business risks loss of market share and loss of reputation. Trust can be built by making a commitment to:

- a. Meet patient needs and preferences when it comes to service delivery.
- b. Ensure patients feel cared for – we use the phrase care and treatment in our everyday language and tend to focus on the technical elements of treatment. Remember to show them you care.
- c. Get it right when patients most need you – when they are in distress.
- d. Manage expectations and create experiences built on continuity of care with individual clinicians. This builds relationships and fosters trust.
- e. Improve communications – both clinical and non-clinical.
- f. Ensure there is transparency in pricing.
- g. Empower your frontline staff – the first contact with the team will form lasting impressions.

The consumer mantra has long been “caveat emptor” (buyer beware). It is not appropriate for the business of dentistry. It should be replaced with “credat emptor” – let the buyer trust.

REFERENCES

1. Graskempner JP. ‘A new perspective on dental malpractice: practice enhancement through risk management’ J Am Dent Assoc. 2002 Jun;133 (6): 752-7.
2. Brown J, Minor DB. ‘Misconduct in Credence Good Markets’, The National Bureau of Economic Research Working Paper No. 18608. Revised in October 2013.





Supervising others

Supervising can be great for career progression, job satisfaction and skill development but are you exposed to more risk?

Dental Protection often gets asked by members whether they require additional indemnity when it comes to advising or supervising their professional colleagues. This could be through an informal arrangement or as a formally recognised mentor. Following on from this, another commonly asked question is whether the member is then liable for any acts by the person they are supervising.

The Singapore Dental Council requires dentists under conditional registration to work for a specified period under the supervision of a fully registered dentist approved by the council.

Every individual practitioner has a duty of care to their patients, but there is also one in a supervising relationship. So, while each individual practitioner has responsibility for patients in whose treatment they are involved, the supervisor should be aware that there could be assumed an ethical dimension even when they are not treating the patient personally. While it does depend on the relationship between the practitioner and the person they are supervising, the supervisor may, in some respects, have a limited responsibility for the outcomes.

SUPERVISEE AUTONOMY

The best way forward in a “true” supervising arrangement is to have clear documentation confirming that the person being supervised is autonomous and working independently. This would mean that regardless of advice and guidance provided by the mentor, it would be very difficult to demonstrate responsibility for treatment on their part.

It may be helpful to consider the following when approaching a supervisee relationship:

- expectations and outcomes agreed upon before any supervision begins
- frequency of sessions, where they will take place and how long for
- professional boundaries.

In any case, a supervisor should never assume that they cannot be considered partly responsible if there are any adverse outcomes from the treatment given by the person being supervised. A supervisor could end up being drawn into investigations if the person being supervised feels that the end result is due to advice or guidance provided by the mentor. Dentists participating in Dental Council mandated supervision of another dentist need to be particularly careful that they are fully aware of the Council's requirements of that arrangement and seek advice from Dental Protection should they feel they are exposed to difficulties or risk related to their supervision of the practitioner concerned.

PART OF THE JOB

Dental Protection views a supervising role as part of professional activity and additional subscriptions are not charged. This is unless you have chosen your membership in a non-clinical category that excludes any involvement with patients.

Implant dentistry is an area that supervisors are sometimes called in to assist with when junior colleagues are working on their first cases. As a practitioner, if you are supervising a colleague who is placing implants, then you must both be appropriately registered by the Dental Council and have adequate and appropriate indemnity protection.

Members are welcome to turn to us for advice and support when it comes to taking on a mentoring role, however, we would not normally extend this advice or support to the organisation or individual they may be providing the supervising service for.

Case Study

Gain adequate consent to avoid claims

A claim for compensation due to alleged negligence is often made because the patient has unrealistic expectations about the treatment or outcomes. Even though lengthy discussions may have taken place, unless this is clearly documented in the clinical records that patient may succeed in their claim. Therefore it is recommended to fully document every discussion in the clinical records to validate the patient's consent. Signed consent forms can be helpful, and sometimes mandatory, but the forms should be specific to the individual treatment planned, rather than an all-encompassing, general consent form.

TIPS TO AVOID A CLAIM

Discuss and fully document in the patient's record:

- the purpose of the procedure
- the nature of the treatment (what it involves and timescales)
- what the treatment will achieve (taking into account the particular concerns of the individual patient)
- any risks, limitations and possible complications (including rare but significant complications)
- alternative treatments and how they compare
- cost
- post-treatment issues including possible time-off work or the need for future treatment.

CASE STUDY: UNRECORDED DISCUSSION LEADS TO CLAIM FOR NEGLIGENCE

A clinician examined a patient who asked whether something could be done to replace his upper right second premolar tooth. The patient had browsed through the literature in the waiting room about implants and bridgework and discussed the various options with the dentist.

The dentist recalled fully discussing the concept of an implant-retained prosthesis and the cost for such a procedure. He also advised his patient that a three-unit bridge using both the upper first molar and premolar as abutments was another alternative. The patient decided to go ahead with the bridgework because it would be quicker and less expensive.

The dentist made a three-unit bridge as agreed, but unfortunately the patient found it difficult to tolerate because he was getting food caught underneath it. By mutual agreement the bridge was removed, before making a crown and a porcelain inlay to restore the distal and mesial abutments respectively.

The dentist carried out some further preparation on the molar tooth and fitted the crown at the following visit. Unfortunately the patient experienced pain from the crowned tooth, which subsequently had to be root-treated.

NEGLIGENCE CLAIM

The patient instructed a lawyer to make a claim in negligence against the dentist alleging that he had not warned of the risks of

preparing the tooth for a coronal restoration, nor had he fully explained the advantages of having the space restored with an implant.

Although the dentist recalled discussing the various options and material risks with the patient, there was unfortunately nothing entered in the records to support his claim that the consent process had been carefully completed. Given there is a legal and ethical obligation to create and retain appropriate records, the very absence of a suitable record in the context of a claim is likely to give rise to an overall impression of poor/substandard care and leaves a court or a decision-maker with an unfavourable view of a clinician's practice, whether that is fair or not. Similarly, in the absence of a good record, the decision on the standard of care may well depend upon the reliability and credibility of the parties and their recollection of the incident.

In view of the lack of supportive records, it was decided it would be difficult to defend the claim and a settlement was effected to compensate the patient for the destruction of the abutment teeth and the costs involved for further restorations of these teeth in the future.

LEARNING POINTS

- Unless conversations and warnings are recorded contemporaneously in the notes, they may well be deemed not to have occurred when a problem subsequently arises and the patient presents a different version of events to that presented by the dentist.





CASE STUDY 2: OUT OF SHAPE

A middle-aged female patient had badly imbricated lower incisor teeth. She responded to an advertisement placed by a dentist who declared a special interest in cosmetic dentistry.

After an initial consultation, various options were outlined in her treatment plan that ranged from orthodontic treatment and crowns, to the most conservative option of reshaping the tooth using enamel reduction and the selective addition of bonded composite. The patient was unsure about using fixed orthodontic treatment, even though it could achieve more than selective reshaping, so she opted to have the four lower incisor teeth crowned.

After having the crowns fitted, the patient was still unhappy with the appearance of her lower incisors. Although the buccal aspects of the teeth were now aligned, any view from above the incisal edges (the patient was short in stature so this became an important consideration) would reveal a strikingly excessive lingual to buccal width of the two teeth that had previously been instanding. As a result, the patient refused to pay for the crowns and threatened legal action.

“ ”

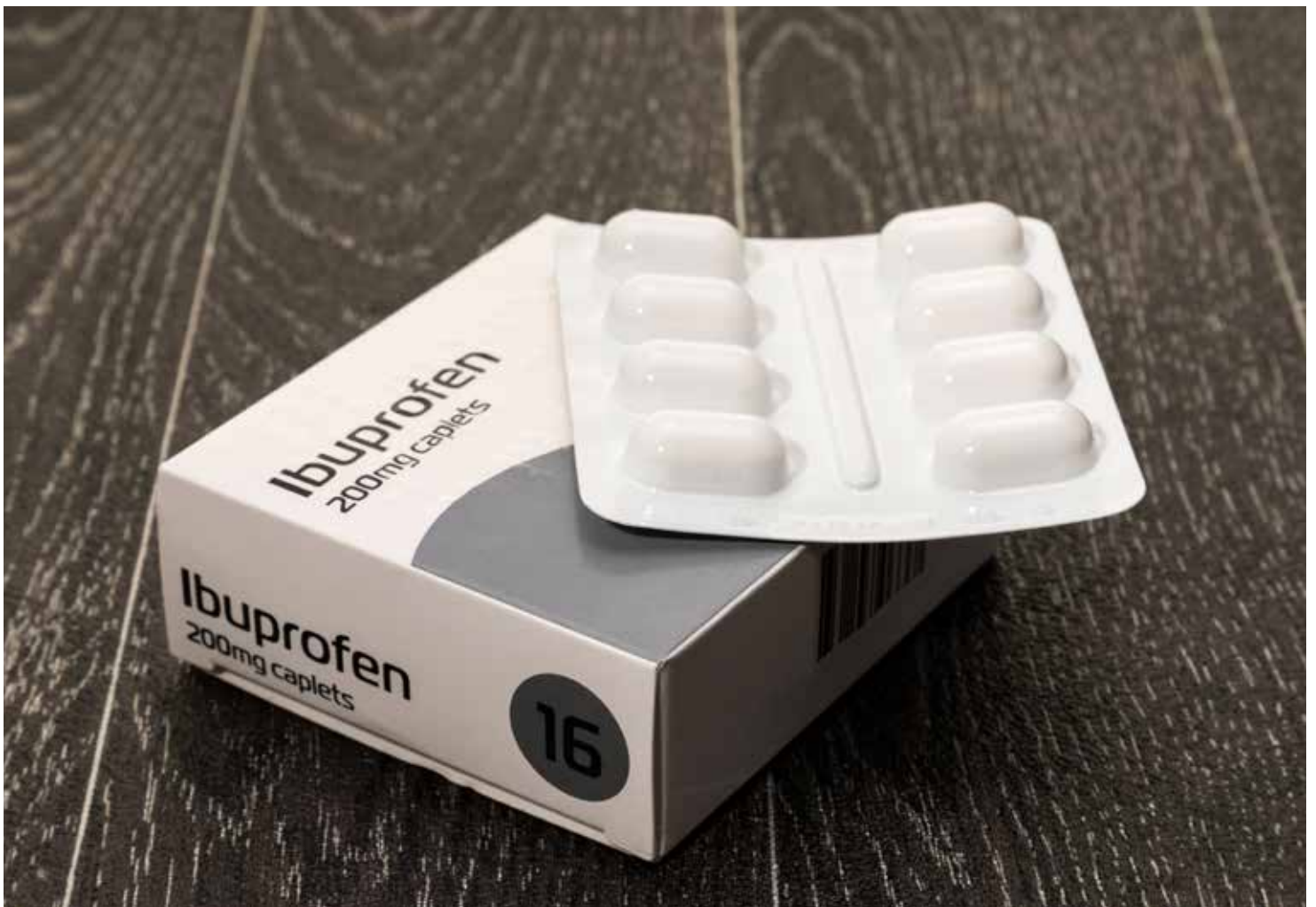This fact had not been considered or discussed with the patient and as a result the dentist was open to criticism given that treatment had been provided without informed consent.

On investigating the background to the case, it transpired that the patient had been shown several 'before' and 'after' pictures of cases where crowded and badly angulated teeth had been corrected into normal alignment. In none of these cases had there been any instance where a tooth ended up with excessive buccal to palatal width, and nor had there been any discussion of this possibility in the pre-treatment consultation between dentist and patient.

An expert opinion was sought, which stated that given the original position of the teeth it was never likely to be possible to create well-aligned teeth of normal dimensions without devitalising the teeth and placing posts and cores. This fact had not been considered or discussed with the patient and as a result the dentist was vulnerable to a successful claim, given that treatment had been provided without informed consent. Dental Protection assisted the dentist to achieve an amicable settlement without the involvement of lawyers.

LEARNING POINTS

- **Whatever the treatment plan, all options need to be given to the patient in order for them to give valid consent to the treatment that is finally selected. If the information provided by the clinician to the patient is incomplete or not accurate, the consent process is very likely to be challenged if the patient is dissatisfied with the outcome.**



Case Study

An adverse reaction to ibuprofen

A patient completed a medical history form for treatment under sedation. Under the allergies section was the entry: 'Allergic to aspirin – facial swelling'.

The dentist, on his own admission, stated that the patient was seen for two appointments with regard to removal of a lower carious wisdom tooth. At both of these consultations, the patient confirmed his allergic reaction to aspirin and even noted the severity of the reaction by indicating he had a facial swelling from a previous reaction.

The wisdom tooth was removed and the dentist provided written and verbal postoperative instructions which included advice to take paracetamol and ibuprofen.

The patient rung later that day to advise he had developed a facial swelling with itchy skin and shortness of breath.

The patient confirmed he had taken ibuprofen and shortly afterwards he developed the described adverse symptoms. The dentist advised the patient to immediately attend the local Emergency Department (ED). He also promptly emailed and phoned the (ED) to alert them of the procedure that had been provided along with medication taken by the patient.

The dentist was not aware of the crossover of the allergic nature of aspirin and ibuprofen even though he knew they were both NSAIDs.

A few hours later the dentist rung the patient to ensure he was alright. The wife of the patient answered and thanked the dentist for his prompt advice and referral to the ED. The patient had been admitted to hospital but was now comfortable and due to be discharged tomorrow morning.

LEARNING POINTS

- It is important that appropriate action is taken on the information in a medical history and if there is any concern about interactions and side-effects, every opportunity should be taken to explore such issues further.
- Thankfully, even though the patient became aware the member had not provided appropriate advice, the member's immediate action and engagement with the patient diffused the situation.

Case Study

The retained root and consent



@mediaphotos@gettyimages.co.uk

A patient attended a new dentist for the first time, complaining of problems with a broken tooth. The patient had not seen a dentist for many months prior to that and was aware that the tooth had been progressively breaking; as she was now experiencing discomfort, she wanted the tooth to be removed. The tooth that was breaking was tooth 23 and was the abutment for an adhesive cantilever bridge replacing the missing tooth 22. The patient explained that she was keen to have implants provided in the near future as she did not want gaps at the front of her mouth, nor did she want another bridge.

The dentist carried out the usual assessments and investigations and took a periapical x-ray of the area, which identified a grossly carious 23 with a periapical area. Even though the x-ray image was not clear, with good lighting, a buried root could also be seen at 22. The dentist did not record that a retained root was present at 22; however, he did recall telling the patient of it at the subsequent appointment, advising that as it was deeply buried and not causing problems it could be left in situ. At the appointment to remove the grossly carious 23, surgery was required as the tooth was so badly decayed.

The dentist raised a flap, removed the tooth and sutures were placed. The patient did not return for a review and the dentist did not see the patient again.

Some time later, the dentist received a letter of complaint. The patient reported that six months after removal of the broken tooth 23 she had attended another practice to discuss implant treatment at the site of the 22/23. The new practitioner had advised the patient that in order to go ahead with dental implant treatment, she would need to have the retained root 22 removed first as it was

at the site where an implant would be placed. This would involve a surgical procedure, followed by a period of healing prior to implant placement. The patient was confused as she was not aware of the retained root of 22 and understood that the root of 23 had already been removed six months earlier. The new dentist showed the patient the retained root, identified following a cone beam CT scan and which on careful review was also visible on a PA film that had been exposed.

The patient's complaint to the earlier dentist was that he should have identified that there was another root present six months earlier and, had she been told of its presence or that it may need to be removed to have implants, she would have opted to have it removed at the same time even when there were no symptoms.

The patient would have preferred to avoid a second, additional surgery, and could have avoided waiting another six months for healing. The dentist could recall telling the patient about the root, but the records did not reflect the conversation and there was no report in the records that a retained root at 22 was present. The dentist's view was that even if he had identified it, as it was asymptomatic at the time, he would not have removed it, as there was no indication for its removal and this would have been the advice given to the patient.

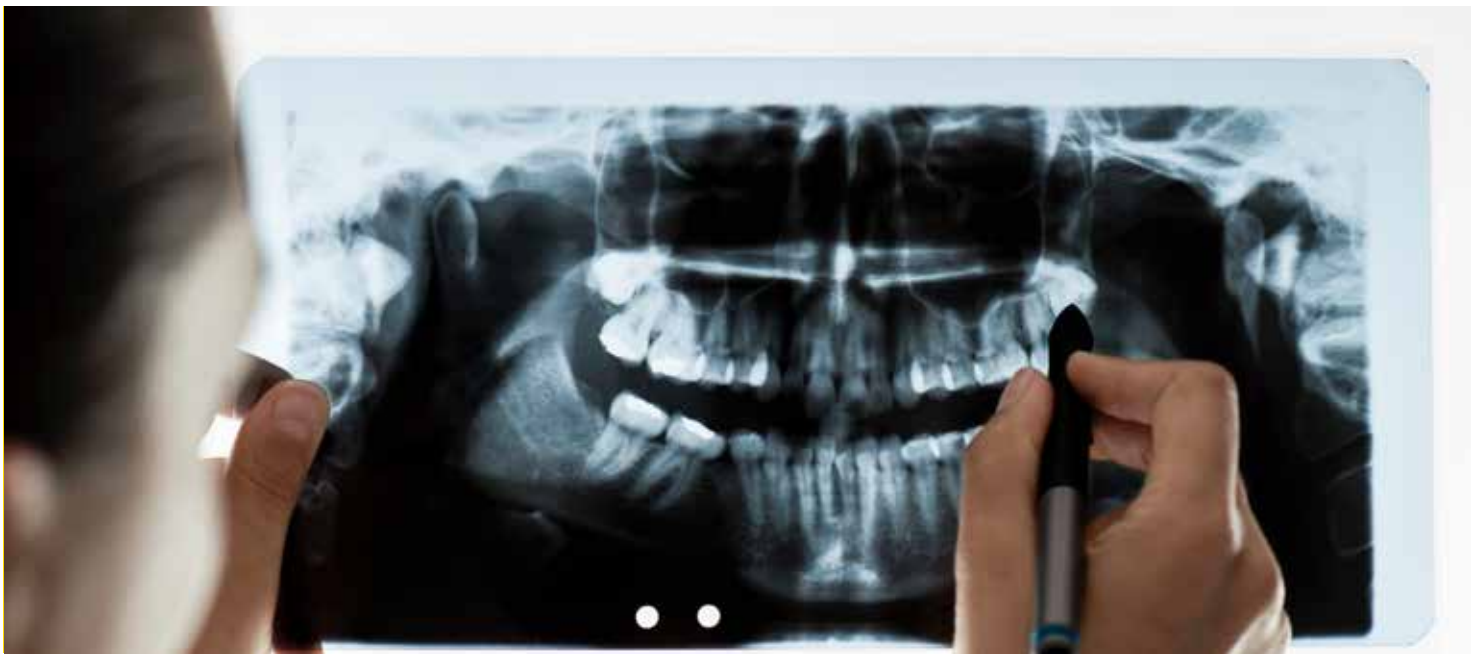Dental Protection suggested to the dentist that his records did not reflect the nature of the conversation that took place with the patient when she first attended with the broken 23. This was identified as an area of vulnerability. Concern was also raised in that the patient was not informed of all the risks or options of leaving a root in situ, including that a second surgical procedure would be required if it needed removal in the future

prior to implant placement, and therefore it could be argued that valid consent had not been obtained when the 23 was extracted.

Dental Protection discussed with the dentist whether they would be prepared to offer a refund of the cost of the extraction at 23 in view of the patient's dissatisfaction, or alternatively consider offering a contribution towards the cost of extraction at 22. It was considered that as the surgery to have the 22 removed could have been avoided, a contribution to this amount would be preferable. The patient was asked to send a copy of the treatment plan and invoice from the new practitioner to demonstrate the cost to have 22 extracted. With Dental Protection's advice and assistance, a letter was drafted that offered the patient an apology, and the complaint was resolved with a contribution towards the cost of the extraction of the retained root at 22.

LEARNING POINTS

- Ensure that the records accurately represent the true nature of any conversation that takes place and the advice given.
- The material risks need to be discussed with patients, which should be tailored to the specific patient. This includes giving the patient information about the treatment options and pros (benefits) and cons (risks) of these options.
- In this case, the patient had explicitly expressed that she wished to have implants placed in the edentulous sites and the material risk of leaving the root in situ was not identified or discussed.



Case Study

A request for compensation

A patient had attended a practice on three previous occasions, seeing a different dentist at each appointment. He attended the first dentist with a fractured filling at tooth 36, which had been placed many years earlier at another practice. The dentist placed a temporary dressing and advised that the patient return for a check-up and filling appointment.

At the second appointment, the patient saw the practice owner, who carried out an examination and placed an amalgam DO filling at 36. The dentist also diagnosed the early stages of periodontal disease and recommended a course of periodontal treatment. Non-surgical root surface debridement was completed over two visits and it was advised that the patient return for a three-month follow-up appointment.

The patient did not attend for the follow-up but returned one year later, requesting a scale and polish to remove stains that had built up on the teeth as he had a family function that he would be attending the following week. The patient was advised on the phone by the receptionist that he was due for a check-up, and asked whether he would like to book for his scale and polish at the same time. The patient booked in for the treatment as advised and at the appointment he mentioned that he had experienced some food packing in the region of 36, where the previous filling had been placed. A clinical examination identified that the filling was stable, but the patient was given the options of either smoothing the filling interproximally

or replacing it to see if the contact point could be improved. As the filling had been placed more than one year earlier, a new charge would apply for a replacement filling.

The periodontal treatment was completed, but the patient expressed dissatisfaction at the time as not all of the stains had been removed. It was explained that if he wanted a full stain removal for cosmetic reasons, an additional hygiene appointment would be necessary.

The patient left and the following week a complaint by email was received. The patient was unhappy that not all of the stains had been removed and explained that this was the prime reason for the appointment. He was also not happy that he was going to be charged for a replacement filling when the dentist had identified that there was a problem with it.

Both dentists involved were members of Dental Protection and promptly contacted a dentolegal consultant for advice. An explanatory letter was sent and the patient was offered a refund of the charge that he had paid for the examination and for the scale and polish. The patient responded requesting a refund for the periodontal treatment, and asked for a financial contribution towards his future periodontal care.

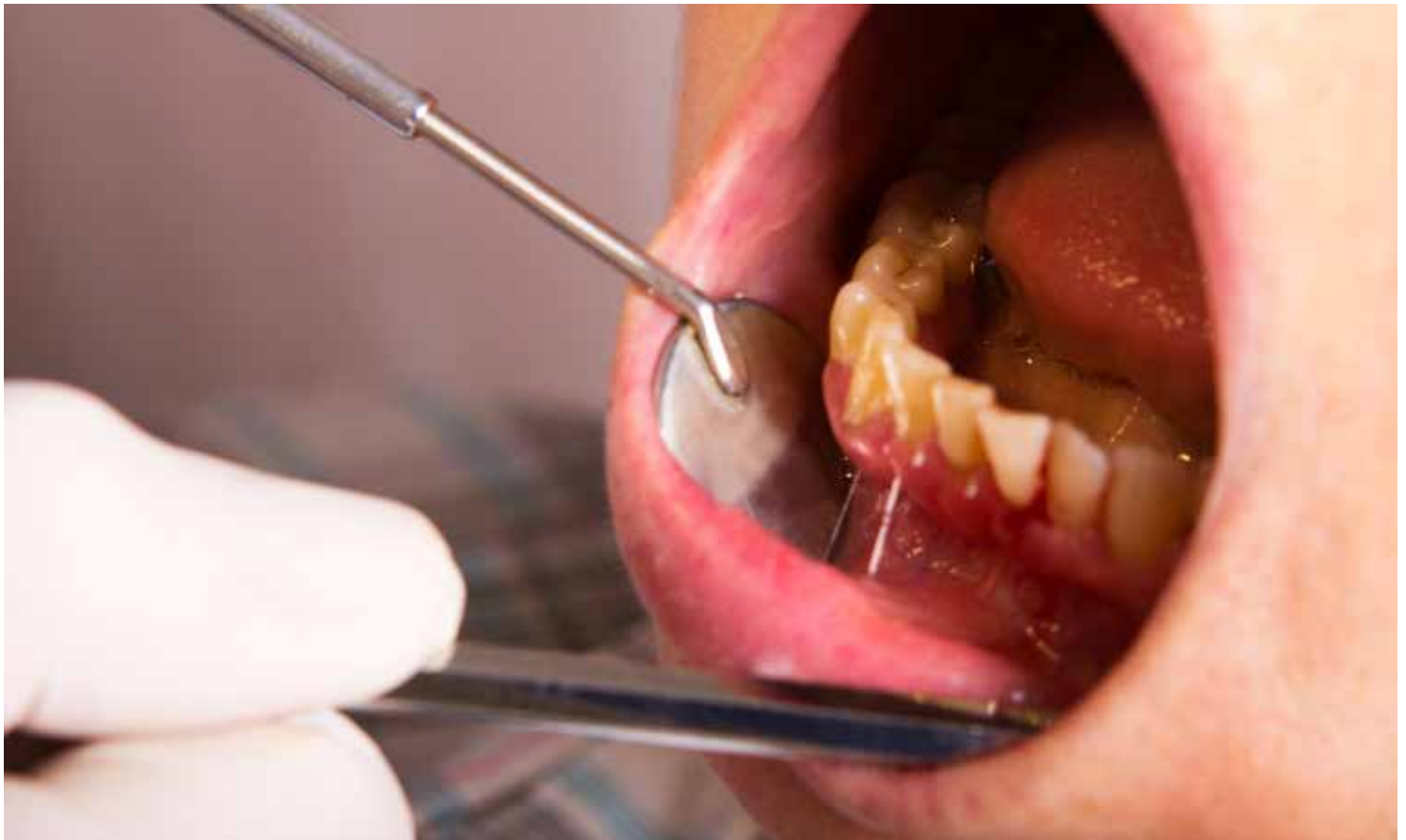A decision was made to offer the patient a refund of the fees for the filling, as a gesture of goodwill and in an attempt to resolve the complaint swiftly and amicably. It was,

however, decided that the offer of additional financial contribution towards a hygiene appointment on top of the refund would have been considered to be betterment, and so this was not offered.

The patient accepted the refund and the complaint was satisfactorily resolved.

LEARNING POINTS

- This case raises the question of what to do when a patient asks for 'compensation'. The term has a different meaning legally than in common use, and whether it means the case should really be considered in the formal sense of the word as a request for damages arising out of negligent care or more simply for some level of financial remedy where service failure has arisen. Situations like this often arise when a patient writes a letter of complaint to a dentist and mentions that they would like financial compensation. A decision needs to be made as to whether the patient is indeed acting as a Litigant in Person, seeking compensation for pain, suffering and loss of amenity (PSLA) or whether the complaint can be managed in line with the practice complaints handling policy, with the offer of a refund of fees or assistance with remedial treatment costs.



Case Study

A lacerated cheek

A dentist received a letter of complaint from an elderly patient who had sustained a soft tissue injury to the lining of the left cheek during the restoration of tooth 38 months earlier.

At the time the dentist had secured haemostasis with sutures, recorded the incident in the clinical notes and offered his sincere apology to the patient.

In his letter of complaint the patient stated that he wanted recompense for negligence and his unpleasant experience. When the letter of complaint was received, as a gesture of goodwill, the dentist decided to refund the cost of the restoration and to waive the charge for his next routine dental examination. The patient was not satisfied with this and stated in his letter that he was considering taking further action with his complaint. The dentist sought assistance from Dental Protection.

Dental Protection advised the dentist that despite accidents like this occasionally happening during dental procedures, it might be considered that the cheek was insufficiently retracted and therefore there was a breach of duty of care to the patient.

However, it was recognised that the injury was transient; probably no worse than could have been sustained by cheek biting and the patient would have likely recovered. In complaining three months after the incident, the patient was very likely seeking some compensation for what he considered was negligence on the part of the dentist leading to an unpleasant experience.

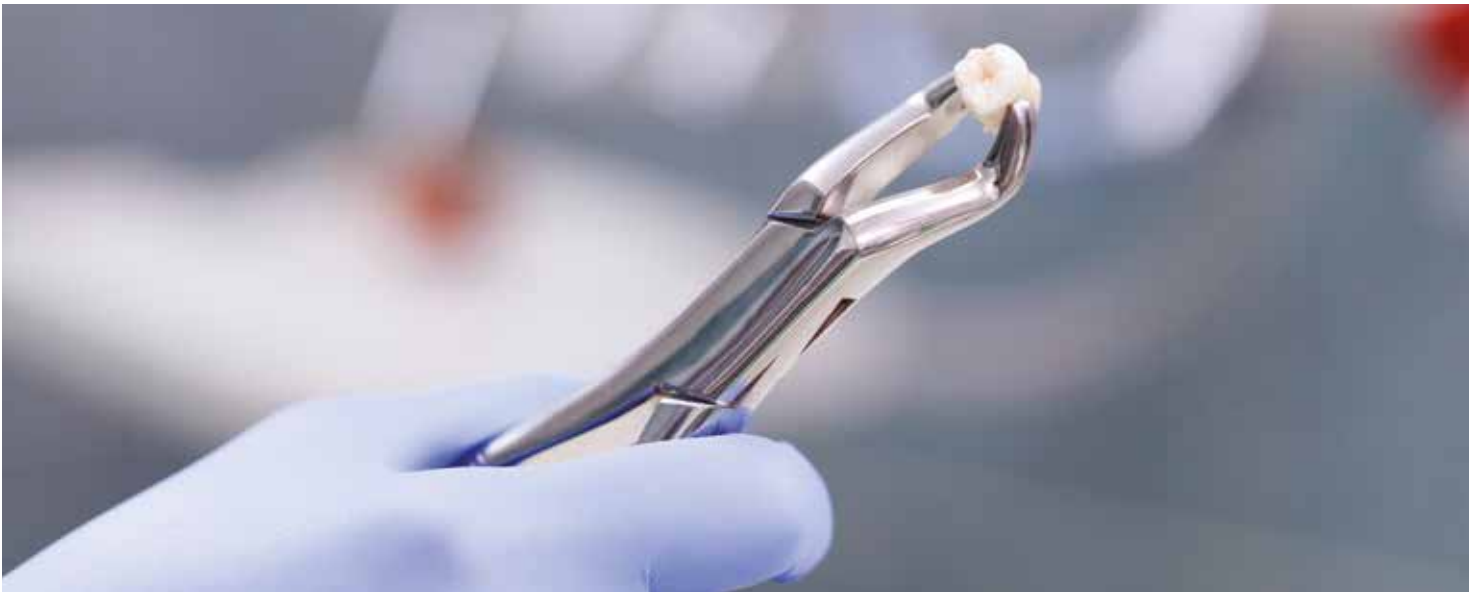Dental Protection advised the dentist to write a further letter to the patient, offering an apology and explaining that despite endeavouring to provide treatment in a caring and considerate manner, treatment of the molars at the back of the mouth requires the retraction of the soft tissues (tongue and cheek) which can be difficult, and occasionally these soft tissues may be accidentally damaged despite the best efforts of the dentist.

As with cheek biting, any small injuries in the mouth heal very quickly and there is rarely any long-term damage. The dentist mentioned that if the patient had contacted him in the days or weeks immediately following the incident, he would have been pleased to have provided all necessary care. The dentist then went on to say that he hoped that the patient

would be happy with the explanation and reimbursement of the costs of the restoration and, if not, then could he write again outlining what he would consider a suitable response. No further correspondence was received from the patient.

LEARNING POINTS

- **If an unexpected outcome arises whilst treating a patient, keep them informed.**



Case Study

A failed extraction handled appropriately

A patient, who had originally been seen by another dentist within the same practice six months earlier, attended with a new colleague complaining of a broken tooth. The new dentist identified deep caries at the 47 and carried out further investigations on the tooth.

After exposure of a radiograph, the tooth was deemed to be unrestorable. After speaking to the patient it was established that he had been aware of deep caries previously and did not want treatment on the tooth, namely root canal treatment or a crown, both of which had been offered six months earlier. The patient had been prepared to wait until the tooth broke or caused pain, after which he would agree to an extraction at that stage.

There was no pain from the tooth, however as it was broken, the patient found that he was having difficulty with eating and this had prompted a return to the practice. The radiograph indicated the 47 was grossly carious and was broken below the alveolar bone level; however, there was good bone and periodontal support. There was no evidence of apical pathology. The patient was advised of the risk that the tooth could break during removal. The patient was also informed that whilst all attempts would be made to remove any remaining root fragments, if this was not possible an onwards referral would be required.

The patient was booked for an appointment three days later and as expected, the tooth fractured during removal, leaving the distal root in situ. The dentist attempted to remove the root, however was unable to mobilise it and after 25 minutes stopped the treatment. The patient was informed of what had happened and that a referral would be required.

The referral was duly made. Two days later the patient returned in pain and saw another dentist at the practice. A diagnosis of dry socket was made and appropriate treatment provided. At this point the patient questioned why antibiotics had not been prescribed at the time of extraction and questioned how long they would need to wait for the referral.

One week later a complaint letter arrived. The patient wanted another explanation as to why antibiotics were not prescribed as soon as the dentist knew the root had broken and expressed concern that the dentist had been aggressive and rough during the extraction process.

The dentist requested assistance from Dental Protection and was advised to send a robust reply to the patient outlining the consent process, technique of extraction and postoperative care and management of the patient.

The patient accepted the explanation and no further action was taken.

LEARNING POINTS

- It is essential that a patient understands what to expect from treatment, both in terms of the procedure itself and any likely outcomes.
- A clear record of the consent process, as well as the pre and postoperative advice given to a patient must be entered in the notes.



PROTECT YOUR CAREER MANAGE YOUR RISK



Risk Management Workshops 2019

LEARN MORE

Visit dentalprotection.org



ENQUIRIES

email dplworkshops@sda.org.sg



DURATION

Three hours



DESIGNED FOR

General dental practitioners and specialists



CONTACTS

You can contact Dental Protection
for assistance via the website
dentalprotection.org

Membership

Contact us via the SDA
6220 2588

Or you can speak to an adviser in the UK between 8.00am to
6.30pm Monday to Friday (GMT)

Phone +44 207 399 1400
membership@sda.org.sg

Dentolegal advice

Contact us via the SDA
6220 2588

Or you can speak to a dentolegal adviser in the UK, between 8.30am
and 5.30pm Monday to Friday (GMT)

Phone +44 207 399 1400
+0800 561 1010

DentalAsia@dentalprotection.org

Opinions expressed by any named external authors herein remain those of the author and do not necessarily represent the views of Dental Protection. Pictures should not be relied upon as accurate representations of clinical situations

Dental Protection Limited is registered in England (No. 2374160) and is a wholly owned subsidiary of The Medical Protection Society Limited ("MPS") which is registered in England (No. 36142). Both companies use 'Dental Protection' as a trading name and have their registered office at Level 19, The Shard, 32 London Bridge Street, London, SE1 9SG.

Dental Protection Limited serves and supports the dental members of MPS with access to the full range of benefits of membership, which are all discretionary, and set out in MPS's Memorandum and Articles of Association. MPS is not an insurance company. Dental Protection® is a registered trademark of MPS.